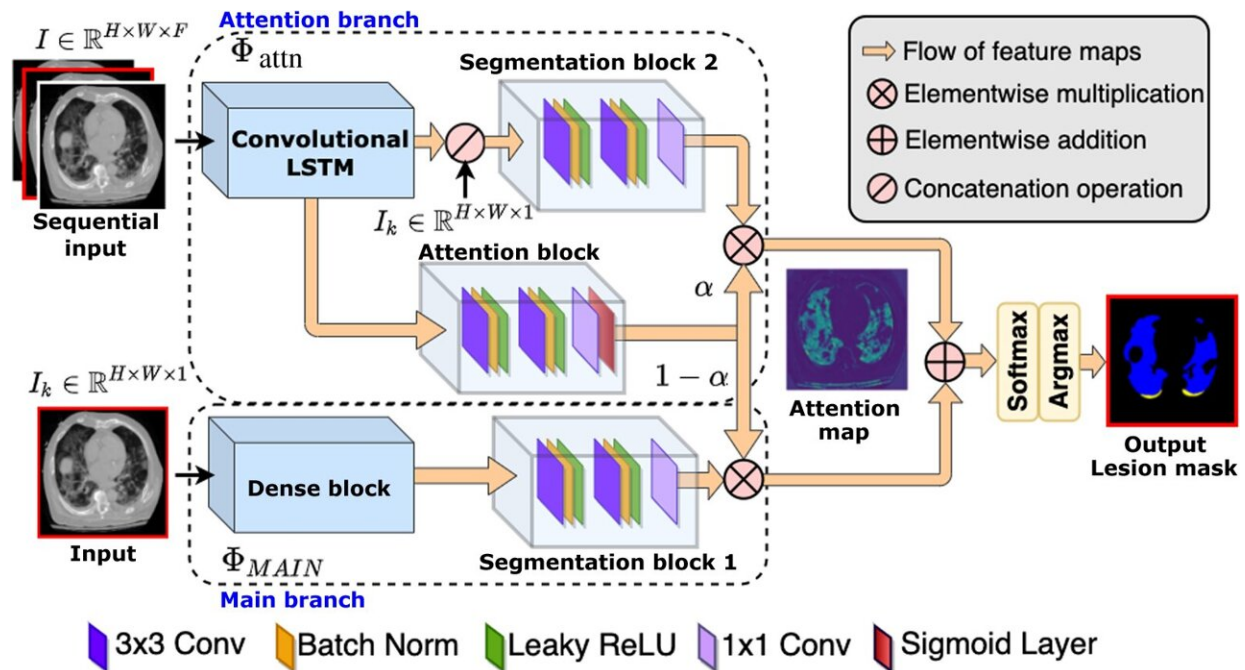


AI model helps diagnose severity of COVID-19 pneumonia

December 15 2022



Framework of the proposed method. Credit: *Journal of Medical Imaging* (2022). DOI: 10.1117/1.JMI.9.5.054001

Cedars-Sinai investigators have developed a new AI model that can rapidly assess the severity of COVID-19 pneumonia.

The automated deep-learning framework, described in the *Journal of Medical Imaging*, helps aid in the evaluation of disease progression and

assist the computed tomographic (CT) monitoring of different treatment responses. It does so as accurately—and significantly faster—as expert manual measurements done by physicians.

"It is extremely difficult for a physician to outline 3D [lung](#) lesions manually on hundreds of CT lung slices as thin as 1 millimeter. AI can make this process very fast and provide the volumetric size of the abnormality in terms of percent of the lung involved," said senior author of the study Piotr Slomka, Ph.D., director of innovation in imaging at Cedars-Sinai and a research scientist in the Division of Artificial Intelligence in Medicine and the Smidt Heart Institute.

"Knowing the correct size of the lesions helps give a more accurate assessment of the patient's condition and ultimately helps providers decide the best treatment option," Slomka explained.

While many people who are diagnosed with COVID-19 only experience mild symptoms, some go on to develop more serious complications, including COVID-19 pneumonia. COVID-19 pneumonia is a [lung infection](#) that causes fluid and inflammation in the lungs, which can potentially become life-threatening.

Currently, CT scans are used to assess disease trajectory and patient outcome in patients with COVID-19 pneumonia. However, the reports do not currently include quantitative measures of the disease burden lesion, such as volume, density and type of abnormality, which can greatly improve the prognosis in patients with COVID-19.

"Despite being demonstrated to predict clinical deterioration in COVID-19 patients, these type of CT-derived quantitative lung measures are not part of the clinical routine because they require manual segmentation of the lung lesions, which is very time-consuming even for the experienced technologist or physician," Slomka said. "And there isn't

always a lot of time."

To help overcome these issues, Slomka and his team created a rapid automated alert system for COVID-19-related abnormalities that could be of great benefit in these situations.

The team developed a new, fully automated deep-learning framework for fast multiclass segmentation of [lung lesions](#) in COVID-19 pneumonia using both contrast and noncontrast CT images with different acquisition protocols at a variety of institutions.

Slomka and colleagues then evaluated the performance of the AI model by comparing its readings to manual readings done by experts on datasets from 197 patients who were diagnosed with COVID-19 with a positive reverse-transcription PCR test, 68 unseen test cases, and 695 independent controls.

They found the AI model had similar accuracy as an expert's manual measurements but with rapid performance (as little as a few seconds for over 100 slices of the entire 3D lung scan, as compared to 30-45 minutes for the expert's manual annotation) that is suitable for use in the clinic setting.

"AI-assisted [image analysis](#) could help improve the clinical assessment of patients with COVID-19," Slomka said.

The software is already being used in multicenter clinical studies of radiological signs and clinical severity of new SARS-CoV-2 variants.

More information: Aditya Killekar et al, Rapid quantification of COVID-19 pneumonia burden from computed tomography with convolutional long short-term memory networks, *Journal of Medical Imaging* (2022). [DOI: 10.1117/1.JMI.9.5.054001](https://doi.org/10.1117/1.JMI.9.5.054001)

Provided by Cedars-Sinai Medical Center

Citation: AI model helps diagnose severity of COVID-19 pneumonia (2022, December 15)
retrieved 3 May 2024 from

<https://medicalxpress.com/news/2022-12-ai-severity-covid-pneumonia.html>

This document is subject to copyright. Apart from any fair dealing for the purpose of private study or research, no part may be reproduced without the written permission. The content is provided for information purposes only.