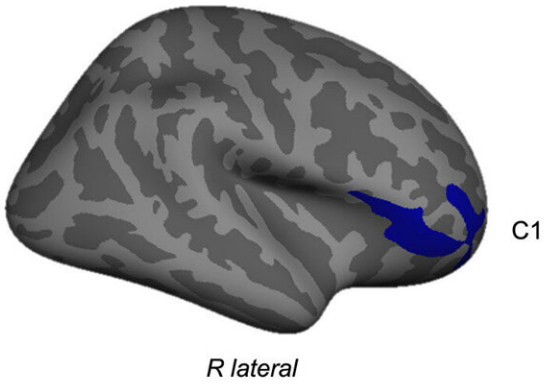


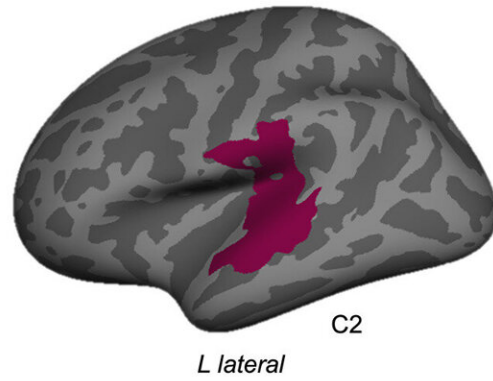
Brain structural differences observed in children with conduct disorder with and without childhood maltreatment

February 7 2023

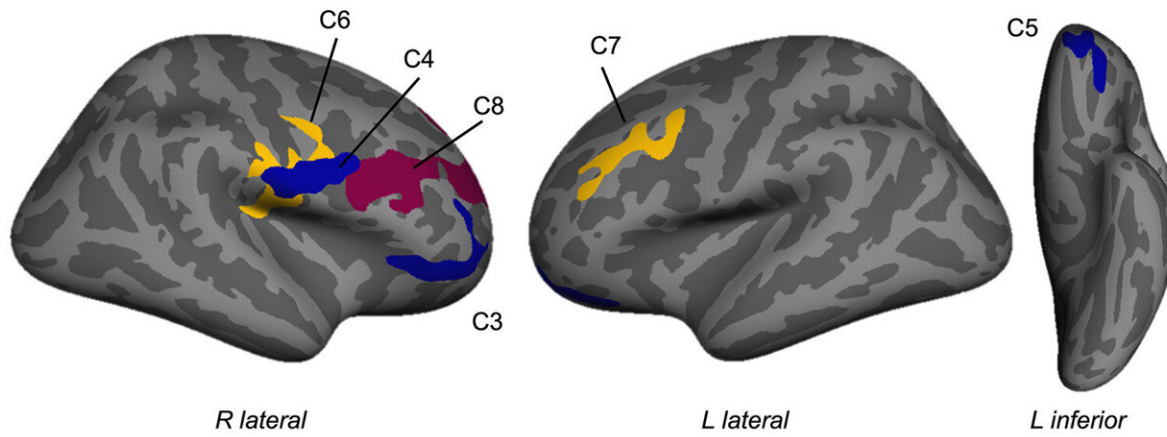
A) CD-all vs HC (CD-all < HC)



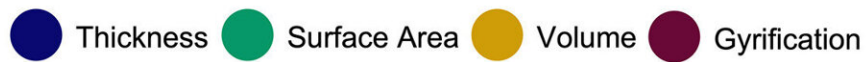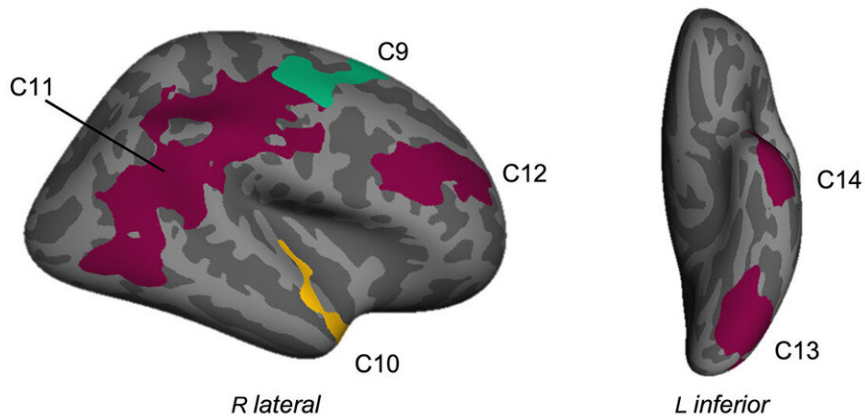
B) CD/- vs HC (CD/- > HC)



C) CD/+ vs HC (CD/+ < HC)



D) CD/+ vs CD/- (all CD/+ < CD/-)



Group differences in cortical thickness, surface area, volume and gyrification when controlling for sex, age, site, and total intracranial volume^a. A) Relative to HCs, the CD-all group demonstrated reduced cortical thickness in the right pars orbitalis of the inferior frontal gyrus (C1). B) CD participants without a history of maltreatment showed significantly greater gyrification in the left superior temporal gyrus (C2) compared to controls. C) CD youth with a history of maltreatment demonstrated lower cortical thickness in the right pars orbitalis of the inferior frontal gyrus (C3), the right postcentral gyrus (C4) and the left lateral orbitofrontal cortex (C5) relative to controls. They further showed lower volume in the right postcentral gyrus (C6) and left rostral middle frontal gyrus (C7), and lower gyrification in the right rostral middle frontal gyrus (C8). D) Comparing CD participants with versus without maltreatment revealed that the maltreated subgroup displayed lower surface area in the right precentral gyrus (C9) and lower volume in the right superior temporal gyrus (C10). They also showed lower gyrification in a large cluster in the supramarginal gyrus (C11), as well as in the right rostral middle frontal (C12), left fusiform (C13) and left inferior temporal gyri (C14).^a Total intracranial volume was not controlled for in the cortical thickness analyses. CD=Conduct Disorder; HC=Healthy Controls. CD/-=Conduct Disorder without maltreatment history; CD/+ =Conduct Disorder with maltreatment history. Credit: *Biological Psychiatry: Cognitive Neuroscience and Neuroimaging* (2023). DOI: 10.1016/j.bpsc.2022.12.012

Characterized by antisocial behaviors and low academic achievement, conduct disorder (CD) impacts an estimated 9.5% of individuals in the United States.

Childhood maltreatment is a major risk factor for CD. Past CD studies have identified structural alterations in various brain regions, such as those implicated in emotion processing, learning, and social cognition. A new study appearing in *Biological Psychiatry: Cognitive Neuroscience and Neuroimaging*, has now assessed whether youths with CD who experienced [childhood maltreatment](#) differ at the brain level from those with CD without a history of maltreatment.

The research, led by Marlene Staginnus, a Ph.D. student at the University of Bath, UK, tested the ecophenotype model, which proposes that maltreatment-related psychopathology is distinct from forms of psychopathology that do not develop as a result of childhood maltreatment. The study included 146 healthy controls and 114 youths with CD. The researchers collected structural MRI data to study cortical structure, including the volume, area, and thickness of the cortex, the outer layer of the brain.

Graeme Fairchild, Ph.D., Department of Psychology, University of Bath, Bath, UK, the senior author on the paper, said, "Our findings have important implications for theory, research, and [clinical practice](#) for those working in mental health or forensic services for young people."

"First, they suggest that, despite having the same diagnosis, conduct disordered youths with and without maltreatment differ from each other in [brain structure](#) and also differ from healthy youth in different ways. To be more specific, the conduct disordered youth with a history of childhood maltreatment showed far more extensive changes in brain structure than the non-maltreated youth with CD—multiple brain regions were affected, and several different aspects of cortical structure (cortical thickness, surface area, and folding) were altered. The maltreated youth with CD also differed more in comparison to the healthy [youth](#) than their non-maltreated counterparts."

In line with the researchers' hypotheses, maltreated and non-maltreated CD youths displayed distinct alterations compared to healthy controls. When combining the CD youths with and without maltreatment into a single group, the CD group displayed lower cortical thickness in the right inferior frontal gyrus.

However, when the maltreated and non-maltreated youths were separately compared with healthy controls, those who had experienced

maltreatment displayed more widespread structural changes in comparison to healthy controls that did their non-maltreated counterparts.

Cameron Carter, MD, editor of *Biological Psychiatry: Cognitive Neuroscience and Neuroimaging*, said of the study, "the authors use structural MRI to measure the changes in brain structure associated with CD and highlight the unique contribution of childhood maltreatment to these changes. The study provides neurobiological insights into the heterogeneity of CD with implications for understanding pathophysiology and informing future treatment development."

These findings may help guide research toward better understanding the prevention, assessment, and treatment of CD. They also beckon to researchers to explore whether there is a distinct pathway between maltreatment and [antisocial behavior](#), or if such brain differences translate to differences in treatment responsiveness.

Dr. Fairchild recommends that "[maltreatment](#) history be assessed in future neuroimaging studies of [conduct disorder](#) and other psychiatric disorders of childhood and adolescence."

More information: Marlene Staginnus et al, Testing the Ecophenotype Model: Cortical Structure Alterations in Conduct Disorder With Versus Without Childhood Maltreatment, *Biological Psychiatry: Cognitive Neuroscience and Neuroimaging* (2023). [DOI: 10.1016/j.bpsc.2022.12.012](#)

Provided by Elsevier

Citation: Brain structural differences observed in children with conduct disorder with and

without childhood maltreatment (2023, February 7) retrieved 25 April 2024 from
<https://medicalxpress.com/news/2023-02-brain-differences-children-disorder-childhood.html>

This document is subject to copyright. Apart from any fair dealing for the purpose of private study or research, no part may be reproduced without the written permission. The content is provided for information purposes only.