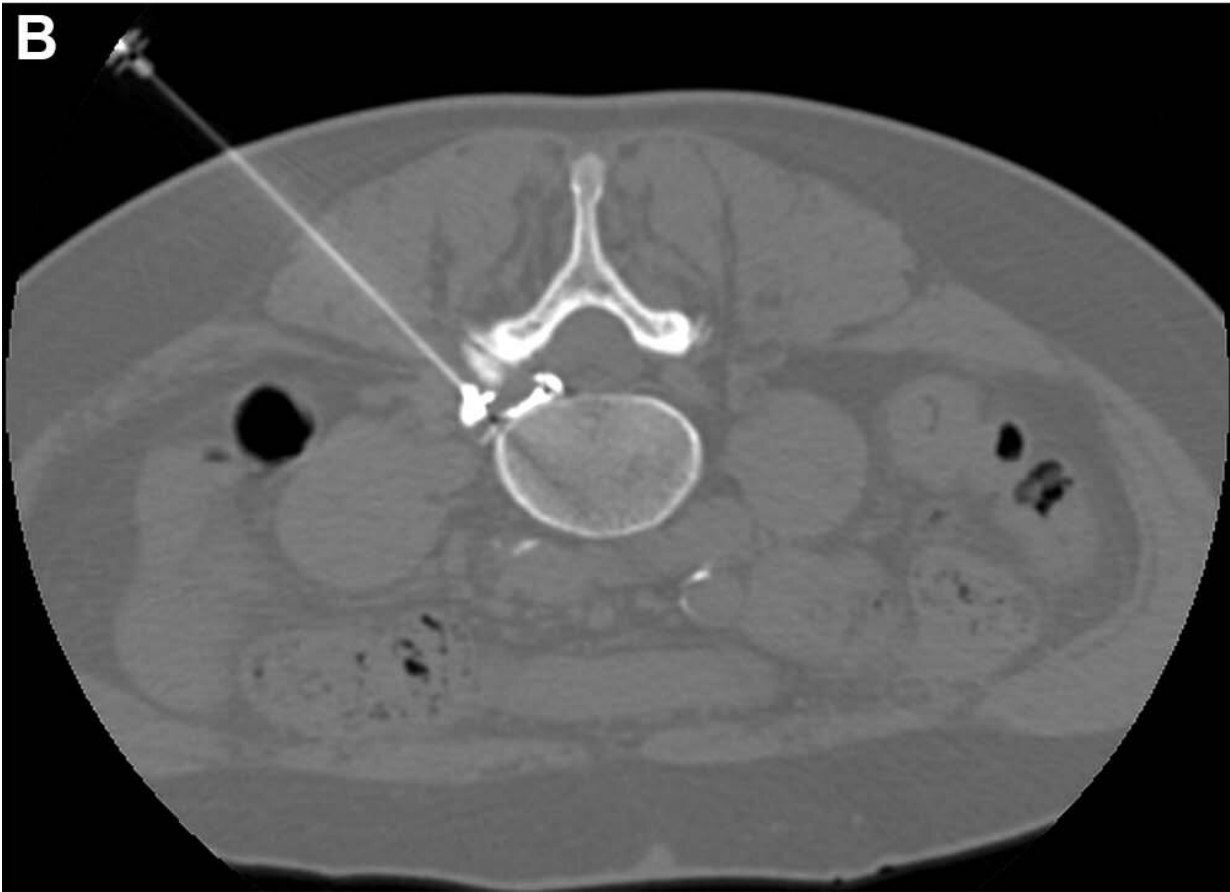
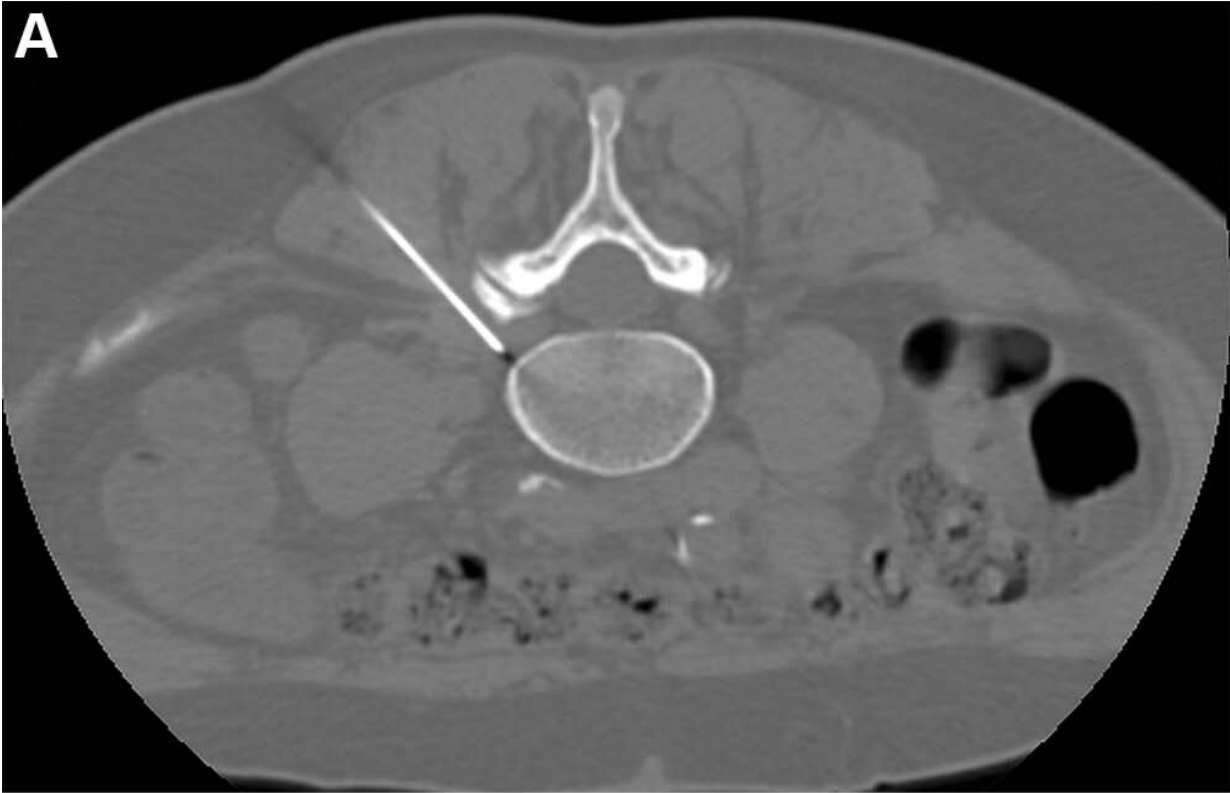

Pulsed radiofrequency with steroid injection brings sciatica relief

March 28 2023



CT-guided pulsed radiofrequency (PRF) with transforaminal epidural steroid injection. A 62-year-old woman underwent PRF followed by transforaminal epidural steroid injection for sciatica due to left contained intraforaminal disk herniation at the L4-5 level. Credit: Radiological Society of North America

Researchers found that a minimally invasive procedure combined with epidural steroid injection treatment led to superior pain reduction and disability improvement over one year in patients with sciatica. The results of the study were published in *Radiology*. The combined treatment performed better than steroid injections alone.

Sciatica is pain that originates along the sciatic nerve, which extends from the back of the pelvis down the back of the thigh. The sciatic nerve is the largest nerve in the body. Treatments to relieve pain include nonsteroidal anti-inflammatory medications, applying heat or cold, and exercising to help minimize inflammation. When the pain is caused by a lumbar disk herniation, surgery is often the [treatment option](#) for pain relief.

"The goal of nonoperative care is to provide the most effective means of symptom resolution, while still avoiding the need for a [surgical procedure](#)," said the study's lead author, Alessandro Napoli, M.D., Ph.D., associate professor of radiology and [interventional radiology](#) at Policlinico Umberto I—Sapienza University of Rome, in Italy.

"However, in many cases conventional approaches are ineffective."

Minimally invasive interventional therapy has become increasingly popular in patients with [sciatica](#) who have become resistant to conservative treatments. Among the available options, transforaminal epidural steroid injection (TFESI) is the only interventional procedure

recommended in clinical guidelines. However, the duration of benefit is usually short, and additional treatments are often necessary.

Another treatment that researchers have studied for sciatica [pain relief](#) is pulsed radiofrequency—a minimally invasive procedure in which pulses of energy from a probe are applied directly to nerve roots near the spine.

For the multicenter randomized trial, researchers wanted to determine the difference in effectiveness between pulsed radiofrequency combined with TFESI versus the steroid injection alone for sciatica pain lasting 12 weeks or longer and not responsive to conservative treatment in patients with due to lumbar disk herniation.

A total of 351 participants (223 men) with sciatica were randomly assigned to receive a single CT-guided pulsed radiofrequency treatment combined with TFESI (174 patients) or TFESI alone (177 patients). Participants were recruited at two tertiary university hospitals and one spine clinic. All procedures were carried out in an outpatient clinic, took only 10 minutes and were performed without general anesthesia.

At four, 12, and 52 weeks there was greater leg [pain](#) reduction and greater disability improvement in participants who received pulsed radiofrequency combined with TFESI compared to the participants who only received the steroid [injection](#).

"The results of our trial demonstrate that a combined treatment of pulsed radiofrequency and TFESI leads to better outcomes at one year following a single 10-minute procedure," Dr. Napoli said.

More information: Alessandro Napoli et al, CT-guided Pulsed Radiofrequency Combined with Steroid Injection for Sciatica from Herniated Disc: A Randomized Trial, *Radiology* (2023).

Provided by Radiological Society of North America

Citation: Pulsed radiofrequency with steroid injection brings sciatica relief (2023, March 28)
retrieved 19 April 2024 from

<https://medicalxpress.com/news/2023-03-pulsed-radiofrequency-steroid-sciatica-relief.html>

This document is subject to copyright. Apart from any fair dealing for the purpose of private study or research, no part may be reproduced without the written permission. The content is provided for information purposes only.