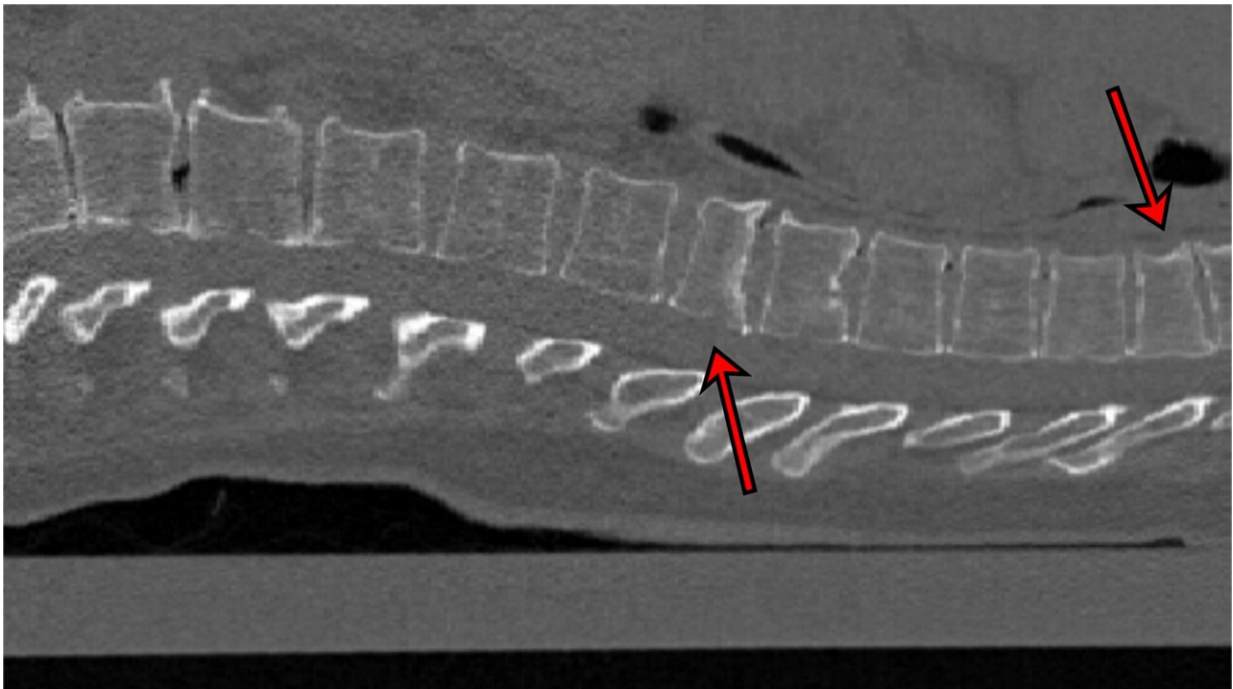


Artificial intelligence detects fractures on CT images for osteoporosis diagnostics

May 1 2023



2D sectional image of a CT scan showing two fractures. They were correctly classified by the AI as moderate (grade 2). The other vertebrae were correctly identified as "normal" (grade 0). Credit: Kiel University

The bone density of many people decreases as they get older. This process, which is known as osteoporosis, often goes unnoticed, even if there are fractures to the vertebral bodies. These fractures could be detected by means of X-rays or computed tomography (CT), but this

does not always occur. For example, because the CT is done for a different reason, a vertebral fracture can be overlooked in the stress of everyday life in the clinic.

Researchers led by Professor Claus-Christian Glüer from the Section Biomedical Imaging at the Department of Diagnostic Radiology at the University Hospital Schleswig-Holstein (UKSH), Campus Kiel, and the Molecular Imaging North Competence Center (MOIN CC), have developed software to improve osteoporosis diagnostics.

The program uses [artificial intelligence](#) (AI) methods to automatically detect indications of osteoporosis and prognostically unfavorable vertebral fractures on computer tomographies taken for a wide variety of reasons. The latest findings were recently presented by Eren Yilmaz, a doctoral candidate in the working group, at the "SPIE Medical Imaging" conference in San Diego, California, and published in the conference transcript in *Medical Imaging 2023: Computer-Aided Diagnosis*.

AI detects nine out of 10 vertebral fractures in CT images

CT images of the chest are often taken to have a look at the lungs, for example. The spine can be seen on the picture but it is not checked, perhaps because the attention is on another problem. "Our program can run in the background during examinations like these. It automatically inspects the spine and gives an indication of any fractures of the vertebrae that might otherwise not have been detected," explains lead author Yilmaz. This is important because the presence of [vertebral fractures](#) significantly increases the risk of further breaks.

The software works using what are known as [neural networks](#). These are algorithms modeled on the way the human brain works, and are often

used to recognize patterns. The AI was tested on 159 CT images of the spine, which came from seven hospitals in Germany. Experienced radiologists examined the images beforehand and discovered 170 fractures. "90% of the cases with fractures were correctly classified by the neural network, as well as 87% of vertebrae without fractures," Yilmaz reports.

In addition, the program is not only able to detect fractures, but also to distinguish between mild fractures (grade 1) and more severe ones (grade 2 or higher). "This diagnosis is crucial for estimating future fracture risks," says Yilmaz. It is particularly applicable to hip fractures, which are associated with a high reduction in quality of life and increased mortality, especially in old age. "We are thus developing an early warning system to prevent serious consequences of osteoporosis."

The technology is not yet available for general use in hospitals. However, it should be possible to use it for research purposes at least in the foreseeable future.

More information: Eren Bora Yilmaz et al, Towards fracture risk assessment by deep-learning-based classification of prevalent vertebral fractures, *Medical Imaging 2023: Computer-Aided Diagnosis* (2023). DOI: [10.1117/12.2653526](https://doi.org/10.1117/12.2653526)

Provided by Kiel University

Citation: Artificial intelligence detects fractures on CT images for osteoporosis diagnostics (2023, May 1) retrieved 21 May 2024 from <https://medicalxpress.com/news/2023-05-artificial-intelligence-fractures-ct-images.html>

This document is subject to copyright. Apart from any fair dealing for the purpose of private

study or research, no part may be reproduced without the written permission. The content is provided for information purposes only.