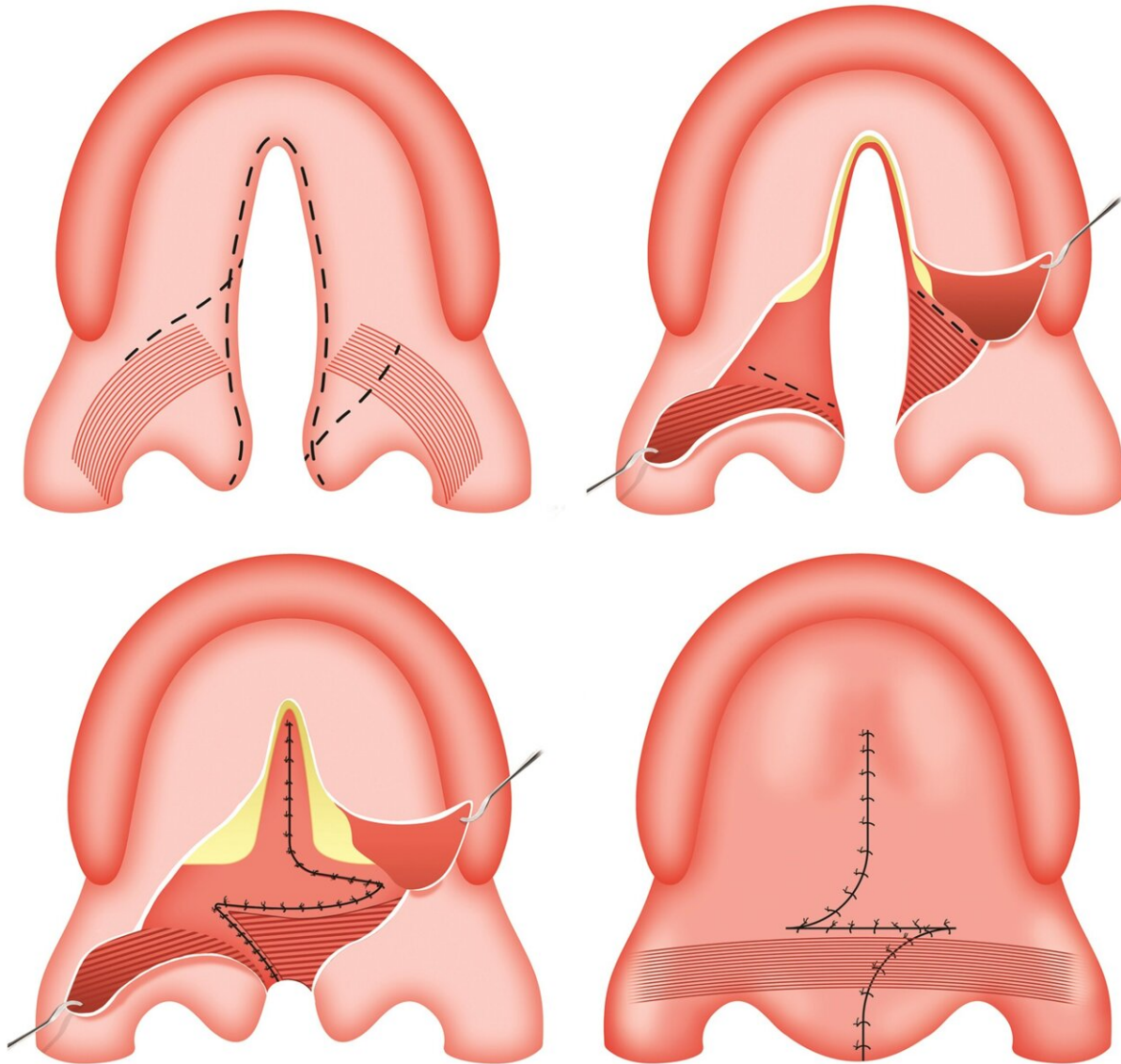


Combined technique provides new choice for cleft palate repair

June 29 2023



The surgical procedures of cleft palate repair using the Furlow palatoplasty.

(Above, left) The markings of incisional design (dashed lines). (Above, right) Separation of the oral and nasal layers, elevation of oral Z-flaps, and designing the nasal Z-flaps incision (dashed lines). (Below, left) Suturing of the nasal layer including nasal Z-flaps. (Below, right) Closure of the oral layer including oral Z-flaps which finalize the palatal muscle reconstruction. Credit: *Plastic & Reconstructive Surgery* (2023). DOI: 10.1097/PRS.0000000000010230

A combination of two established surgical techniques provides good outcomes in repair of cleft palate in infants, reports a study in the July issue of *Plastic & Reconstructive Surgery*.

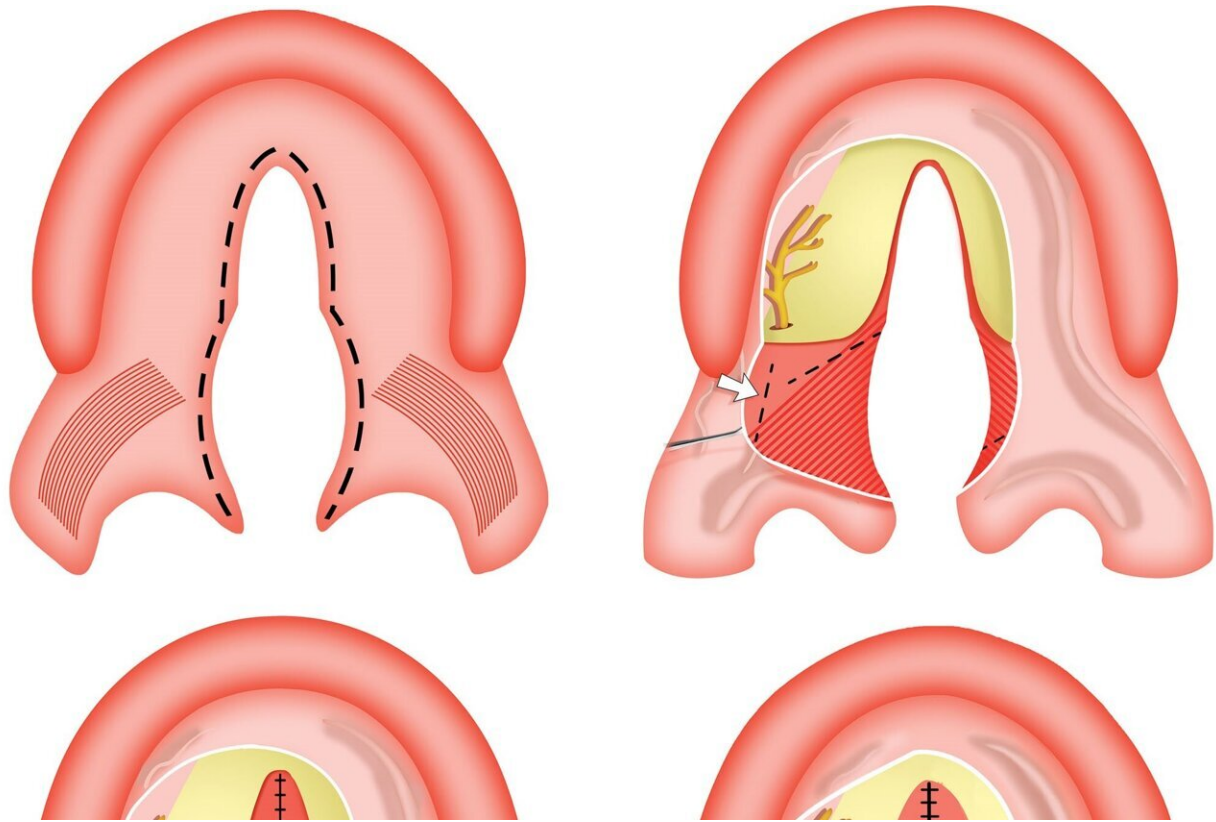
"Based on our experience, the modified Sommerlad-Furlow [S-F] technique provides similar functional outcomes and quality of life, compared to standard surgery," comment senior authors Hanyao Huang, Ph.D., and Bing Shi, Ph.D., of West China Hospital of Stomatology, Sichuan University. "The S-F technique could offer a new choice for cleft palate repair, especially in wider clefts." The study appears as part of an expanded pediatric/craniofacial surgery section, commemorating July as National Cleft and Craniofacial Awareness and Prevention Month.

New approach combines benefits of two classical cleft repair techniques

Modern approaches to cleft palate repair in infants focus not just on closing the cleft but also on functional restoration of the palate as the child grows. The Furlow technique, a double-opposing Z-plasty, is one of the most frequently used procedures for primary cleft palate repair and can significantly lengthen the soft palate. However, Z-plasty results in higher tension of the tissue, which can lead to the risk of oronasal fistula (ONF): a persistent opening between the oral and [nasal cavities](#).

The Sommerlad technique takes a different approach to reconstruction of the palatal muscles. Previous modifications have included the use of a "relaxing incision" on the hard palate in both Furlow and Sommerlad techniques for avoiding the risk of ONF, but this has the potential to lead to inhibition of maxillofacial growth. On the other hand, without the use of relaxing incision, both the Furlow and Sommerlad techniques carry a substantial risk of ONF, especially in infants with wider clefts.

To combine the advantages of these two approaches, Drs. Huang and Shi and colleagues designed a new modified S-F technique. Based on "three principles for a proper palatoplasty," the combined approach included reconstruction of the palatal muscles, lengthening the soft palate by Z-plasty on the nasal side, and the application of nasopharyngeal incision for avoiding the relaxing incision on the hard palate. Drs. Huang and Shi explain, "The nasopharyngeal incision helps achieve the three goals by harvesting more tissue for the oral side while guaranteeing enough tissue on the nasal side for Z-plasty."



The surgical procedures of cleft palate repair using the S-F technique. (Above, left) The markings of incisional design (dashed line) which tend to the oral side to keep more mucosal tissues on the nasal side. (Above, right) Separation and elevation of the oral mucoperiosteal flap (hard palate) and oral mucosal flap (soft palate), releasing the greater palatine neurovascular pedicles, and designing the nasopharyngeal incision on the surface of the medial pterygoid plate (dashed lines at white arrow) and nasal Z-flaps. (Below, left) After proceeding with the nasopharyngeal incision, the nasal mucoperiosteal flap is peeled from the medial pterygoid plate toward the base of the skull (white arrow) and then anteriorly from the palatine bone, suturing the nasal layer of the hard palate, radical dissection of the palatal muscle from the nasal musculomucosal layer on the left side, and Z-plasty flaps is then made on the soft palate of the nasal layer. (Below, right) Complete closure of the nasal layer including inserting and suturing of Z-flaps and suturing of dissected palatal muscular flap on the left side to the surface of the right myomucosal flap. (Below) Closure of the oral layer. Credit: *Plastic & Reconstructive Surgery* (2023). DOI: 10.1097/PRS.0000000000010230

Modified S-F technique may be 'a treatment of choice in wider clefts'

The researchers assessed clinical and functional outcomes of 106 infants undergoing the modified S-F procedure between 2006 and 2011. Results were compared with those of 106 children who underwent the Furlow technique, without a relaxing incision. Average age at cleft palate repair was 1.3 years, with follow-up times of five to 10 years. Cleft width was somewhat greater in infants selected for the S-F technique: median 10 vs. 8 millimeters. Other patient characteristics were similar between groups.

Most outcomes were similar between groups, including the rate of persistent ONF: 7.5% after the modified S-F technique and 6.6% with the Furlow technique. Measures of voice quality and speech intelligibility were similar as well. The rate of severe problems with speech intelligibility was slightly lower in the S-F group: 7.5%, compared to 9.4% with the standard Furlow procedure.

In both groups, more than 80% of patients had good velopharyngeal function, without air leaks between the nasal cavity and mouth. Rates of severe velopharyngeal insufficiency (VPI)—causing "nasal" speech and other symptoms—were 0.9% in the S-F group and 2.8% in the Furlow group. Patient/parent ratings suggested "adequate" [quality of life](#) related to VPI in 80.4% and 78.6% of patients, respectively.

Within the limitations of the study design, the results suggest that the two techniques yield similar outcomes in infants undergoing primary cleft palate repair—"with comparable to slightly better speech outcomes after the S-F technique."

Drs. Huang and Shi and colleagues conclude, "Although the Furlow technique is still popular and effective procedure for primary [cleft palate](#)

repair, the S-F modified technique may be considered a treatment of choice in wider clefts."

More information: Karim A. Sakran et al, Evaluation of Postoperative Outcomes in Two Cleft Palate Repair Techniques without Relaxing Incisions, *Plastic & Reconstructive Surgery* (2023). [DOI: 10.1097/PRS.00000000000010230](https://doi.org/10.1097/PRS.00000000000010230)

Provided by Wolters Kluwer Health

Citation: Combined technique provides new choice for cleft palate repair (2023, June 29) retrieved 27 April 2024 from <https://medicalxpress.com/news/2023-06-combined-technique-choice-cleft-palate.html>

This document is subject to copyright. Apart from any fair dealing for the purpose of private study or research, no part may be reproduced without the written permission. The content is provided for information purposes only.