

Machine learning model identifies mild cognitive impairment from retinal scans

July 10 2023

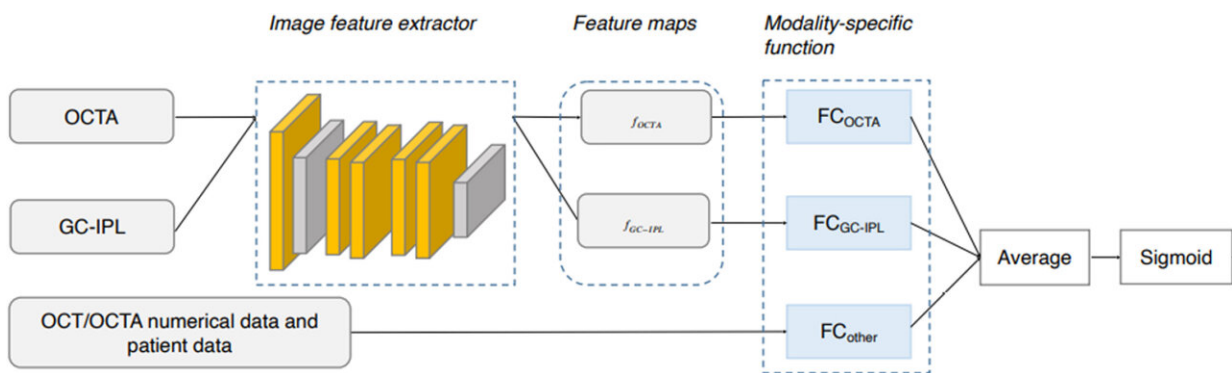


Illustration of the structure of the convolutional neural network (CNN) for differentiation of eyes of subjects with mild cognitive impairment from cognitively healthy controls. The CNN uses a convolutional encoder for the image inputs (GC-IPL and OCTA), image modality specific feature transformations (f_{OCTA} and $f_{\text{GC-IPL}}$), prediction heads for all modalities (FC_{OCTA} , $\text{FC}_{\text{GC-IPL}}$ and FC_{other}) whose outputs are aggregated using averages and then processed through a sigmoid activation function to yield a model score. Credit: *Ophthalmology Science* (2023). DOI: 10.1016/j.xops.2023.100355

A machine learning model developed by Duke Health researchers can differentiate normal cognition from mild cognitive impairment using retinal images from the eye.

The model analyzes [retinal images](#) and associated data and recognizes specific features to identify individuals with [mild cognitive impairment](#).

Publishing in the journal *Ophthalmology Science*, the model demonstrates the potential for a non-invasive and inexpensive method of identifying the early signs of [cognitive impairment](#) that could progress to Alzheimer's disease.

"This is particularly exciting work because we have previously been unable to differentiate mild cognitive impairment from normal cognition in previous models," said senior author Sharon Fekrat, M.D., professor in Duke's departments of Ophthalmology and Neurology, and associate professor in the Department of Surgery. "This work brings us one step closer to detecting cognitive impairment earlier before it progresses to Alzheimer's dementia."

Fekrat and colleagues previously developed a model that used retinal scans and other data to successfully identify patients with a known Alzheimer's diagnosis. The scans—based on [optical coherence tomography](#) (OCT) and OCT angiography (OCTA)—detected structural changes in the neurosensory retina and its microvasculature among Alzheimer's patients.

The current study expands on that work, using machine learning techniques to detect mild cognitive impairment, which is often a precursor to Alzheimer's. The new model identifies specific features in the OCT and OCTA images that signal the presence of cognitive impairment, along with patient data such as age, sex, [visual acuity](#), and years of education and quantitative data from the images themselves.

The researchers reported that the model analyzed retinal pictures and images along with [quantitative data](#) to differentiate people with normal cognition from those with a diagnosis of mild cognitive impairment with a sensitivity of 79% and specificity of 83%.

"This is the first study to use retinal OCT and OCTA images to

distinguish people with mild cognitive impairment from individuals with normal cognition," said co-first author C. Ellis Wisely, M.D., assistant professor in the Department of Ophthalmology.

"Having a non-invasive and less expensive means to reliably identify these patients is increasingly important, particularly as new therapies for Alzheimer's disease may become available," Wisely said.

"The retina is a window to the brain, and machine learning algorithms that leverage non-invasive and cost-effective retinal imaging to assess neurological health can be a potent tool to screen patients at scale," said co-lead author Alexander Richardson, a student in the Eye Multimodal Imaging in Neurodegenerative Disease lab at Duke.

More information: C. Ellis Wisely et al, A convolutional neural network using multimodal retinal imaging for differentiation of mild cognitive impairment from normal cognition, *Ophthalmology Science* (2023). [DOI: 10.1016/j.xops.2023.100355](https://doi.org/10.1016/j.xops.2023.100355)

Provided by Duke University Medical Center

Citation: Machine learning model identifies mild cognitive impairment from retinal scans (2023, July 10) retrieved 27 April 2024 from <https://medicalxpress.com/news/2023-07-machine-mild-cognitive-impairment-retinal.html>

This document is subject to copyright. Apart from any fair dealing for the purpose of private study or research, no part may be reproduced without the written permission. The content is provided for information purposes only.