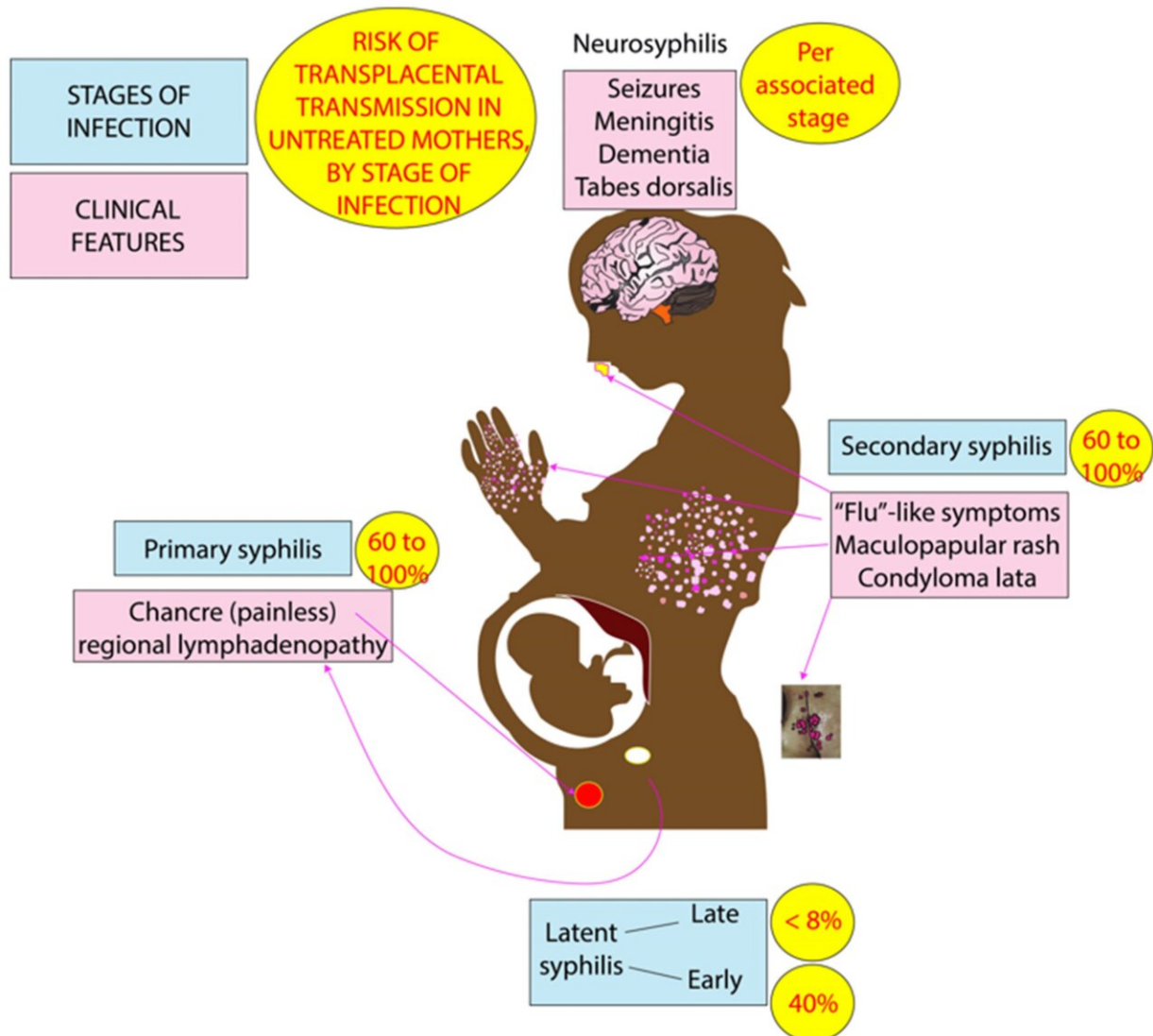


The rising health crisis of congenital syphilis: What physicians can do

December 4 2023, by Tricia Tomiyoshi



Clinical features of perinatal syphilis and risk of maternal-to-fetal transmission. Primary syphilis (painless skin lesions/chancre or regional lymphadenopathy)

and secondary syphilis (flu-like syndrome, maculopapular rash, and skin lesions known as condyloma lata) are associated with 60–100% transmission of infection to the fetus. Latent syphilis with disappearance of symptoms is associated with

Citation: The rising health crisis of congenital syphilis: What physicians can do (2023, December 4) retrieved 9 May 2024 from

<https://medicalxpress.com/news/2023-12-health-crisis-congenital-syphilis-physicians.html>

<p>This document is subject to copyright. Apart from any fair dealing for the purpose of private study or research, no part may be reproduced without the written permission. The content is provided for information purposes only.</p>
--