Medical Xpress

Microscopic colitis explained—and why it's often mistaken for IBS

December 13 2023, by David Bergman

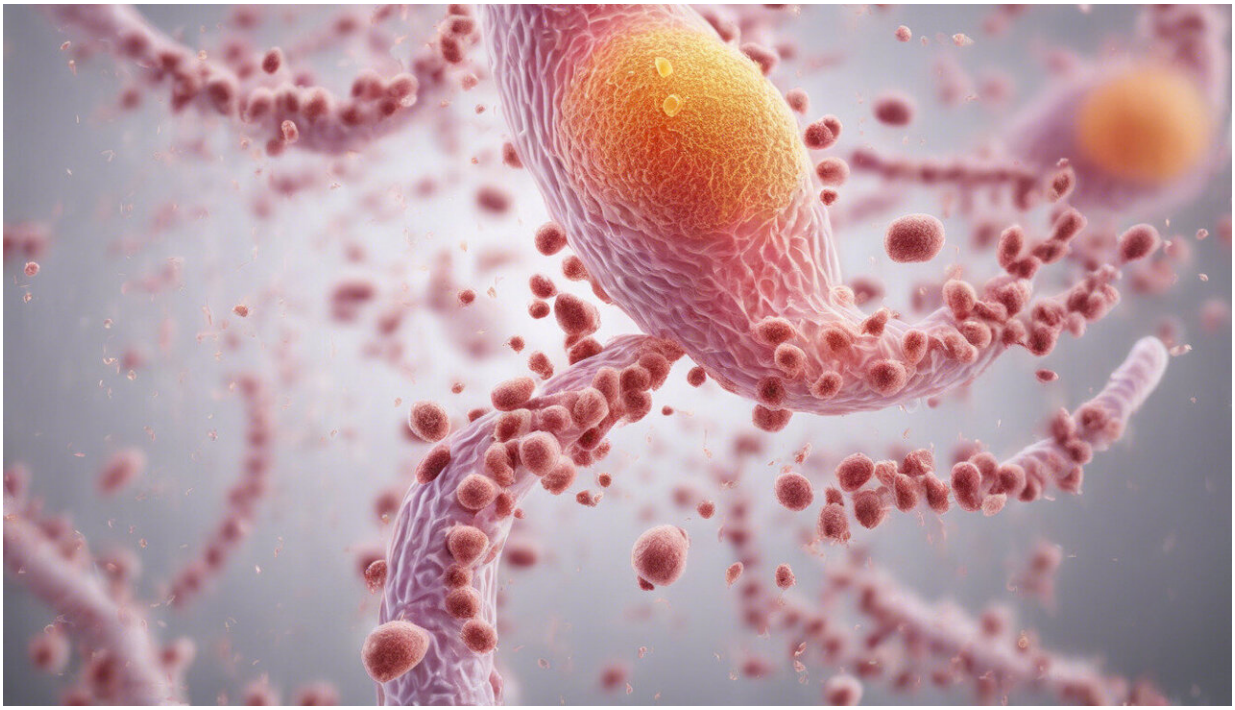

Credit: AI-generated image

In 1976, a Swedish pathologist, C.G Lindström, published a paper describing a colonic anomaly. Through his microscope, he noted that part of the large intestinal wall of one of his patients was thickened. The patient, whose large intestine had been so thoroughly examined, suffered from chronic diarrhea. The pathologist suggested naming the new entity

collagenous colitis, with "colitis" referring to inflammation of the large intestine.

Ten years later, an American pathologist, A.J. Lazenby, noted an increased concentration of white blood cells in the colonic wall in patients experiencing similar chronic diarrhea. She named the condition lymphocytic colitis.

Since patients diagnosed with these two new diseases experienced identical symptoms, had tissue changes only visible through a microscope and responded to the same medication, they were seen as suffering from one entity: microscopic colitis.

Although the medical community gradually became aware of microscopic colitis, the condition was rarely diagnosed. Several factors likely contributed to this, such as the absence of blood in the stools, which is rightly considered a serious symptom requiring a thorough and prompt investigation.

Also, studies have found that microscopic colitis is often misdiagnosed as irritable bowel syndrome, a functional disorder (arising from changes in how the body works, rather than a disease).

Another explanation is, of course, the health care resources required to diagnose the condition.

More people being diagnosed

First, an examination of the large intestine must be undertaken during which tissue samples have to be collected and then these tissue samples must be properly examined by a pathologist who knows what changes to look for.

However, as the awareness of the disease has increased along with the access to the health care resources described above, more people are being diagnosed with microscopic colitis.

In a study examining the diagnosis of microscopic colitis in Sweden from 1990 to 2015, my colleagues and I noted a sharp rise in the curve depicting the number of people diagnosed per year for the first 20 years, followed by a plateau.

What we also noted was that 70% of people with the condition were women and that the average age at diagnosis was around 60 years—although 25% were younger than 45.

In another of our studies, we investigated what symptoms these patients experienced. Almost everyone suffered from watery diarrhea (without blood). Other symptoms included abdominal pain, weight loss, nausea and some patients even experienced fecal incontinence.

Among gastroenterologists, it is well known that patients with this disease often experience stress and anxiety related to their bowel movements. Some may even avoid going outdoors for fear of not making it to a restroom in time. And when going out they always know where the nearest toilet is.

Unfortunately, we do not yet know what causes the disease, but it is considered to be a complex combination of genetic and environmental factors as well as an imbalanced immune system.

Smoking also seems to be a risk factor. People with microscopic colitis who smoke, are diagnosed at a younger age and have more symptoms. On the bright side, there are effective treatments, such as the steroid drug budesonide, usually without any serious side-effects. And people who do smoke and quit may even experience an alleviation of their

symptoms.

Properly diagnosing and treating microscopic colitis can make a huge difference for people with the condition.

Provided by The Conversation

Citation: Microscopic colitis explained—and why it's often mistaken for IBS (2023, December 13) retrieved 9 May 2024 from https://medicalxpress.com/news/2023-12-microscopic-colitis-explainedand-mistaken-ibs.html