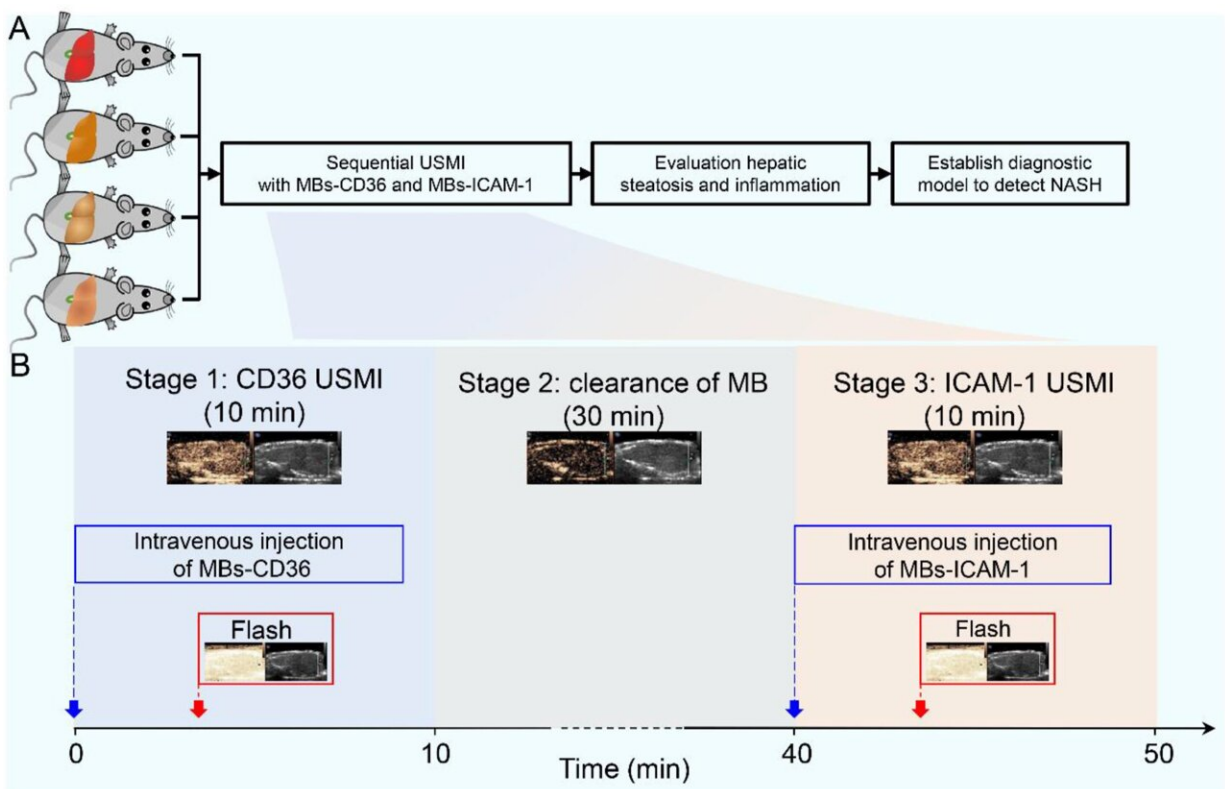


Advancing noninvasive diagnosis of NASH: Potential of sequential ultrasound molecular imaging in NAFLD/MAFLD

January 22 2024



Animal study flowchart and schematic illustration of sequential USMI. Credit: *Liver Research* (2023). DOI: 10.1016/j.livres.2023.11.002

Non-alcoholic fatty liver disease (NAFLD), recently renamed metabolic

dysfunction-associated fatty liver disease (MAFLD), is spectrum of diseases that ranges from non-alcoholic fatty liver (NAFL) to non-alcoholic steatohepatitis (NASH).

Invasive liver biopsy continues to be the gold standard for diagnosing NASH through the histopathological assessment of liver steatosis, ballooning and lobular inflammation. However, this method does have its limitations, including sampling bias, low patient acceptance and potential complications.

Clinical imaging techniques such as ultrasound and [magnetic resonance imaging](#) can detect or quantify liver steatosis, but are unable to differentiate between NASH and NAFLD. Therefore, there is a need to identify noninvasive parameters associated with NASH that can serve as surrogate markers for these histologic features.

In a [study](#) published in the journal *Liver Research*, a group of Chinese researchers detailed a sequential ultrasound molecular imaging (USMI), an emerging strategy for the identification of NASH by visualizing hepatic steatosis and inflammation.

Notably, distinct microbubbles (MBs) were used to target CD36 and ICAM-1 individually, rather than a dual-targeted MB. This approach allows for the differentiation of the signal source (either steatosis or inflammation) and the identification of the predominant pathological change.

"As a noninvasive diagnostic tool, this strategy has the potential to assist in clinical therapeutic decision-making and contribute to [drug development](#) for NASH," says Tinghui Yin, senior author of the study.

"Furthermore, among various sequential USMI-based diagnostic models, the serial testing model showed high diagnostic performance in detecting

NASH, with 95% sensitivity, 97% specificity, 95% positive predictive values, 97% negative predictive values and 96% accuracy."

CD36 is known to be associated with liver steatosis, while elevated ICAM-1 levels are seen in the progression of liver inflammation. Hence, quantitatively visualizing hepatic CD36 and ICAM-1 can provide valuable information in determining the extent of hepatic steatosis and inflammation.

This achievement brings researchers one step closer to the ultimate objective of establishing a viable noninvasive approach for detecting NASH.

More information: Tingting Sha et al, Sequential ultrasound molecular imaging for noninvasive identification and assessment of non-alcoholic steatohepatitis in mouse models, *Liver Research* (2023). [DOI: 10.1016/j.livres.2023.11.002](https://doi.org/10.1016/j.livres.2023.11.002)

Provided by KeAi Communications Co.

Citation: Advancing noninvasive diagnosis of NASH: Potential of sequential ultrasound molecular imaging in NAFLD/MAFLD (2024, January 22) retrieved 28 April 2024 from <https://medicalxpress.com/news/2024-01-advancing-noninvasive-diagnosis-nash-potential.html>

This document is subject to copyright. Apart from any fair dealing for the purpose of private study or research, no part may be reproduced without the written permission. The content is provided for information purposes only.