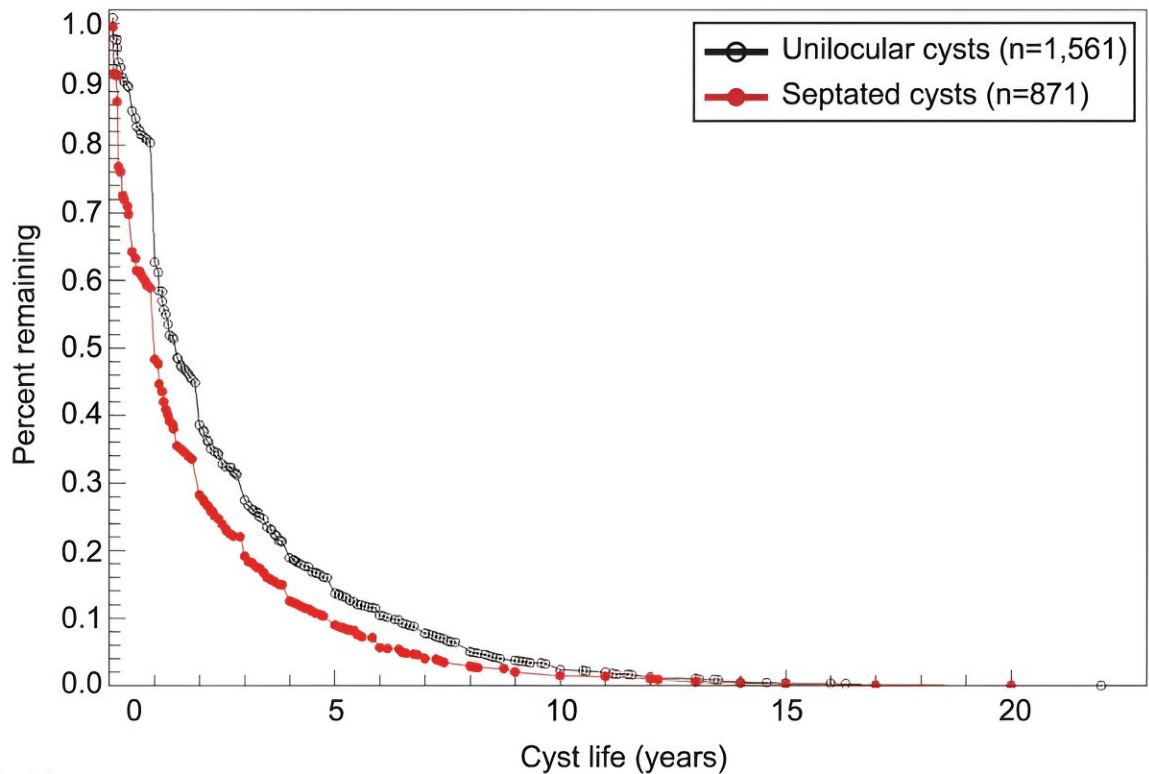


Study provides clinician guidance on follow-up for ovarian cysts

January 11 2024, by Elizabeth Chapin



At risk (n)

Unilocular	1,561	249	50	7	2
Septated	871	90	18	3	1

Resolution of incident unilocular cysts and septated cysts. Ovarian cysts found on transvaginal ultrasonography were characterized by structure. The number of cysts remaining as a function of time after the appearance of the first cyst was converted to the percent of ovarian cysts remaining. Unilocular and septated cysts were monitored until resolution. Results were obtained using the Kaplan-Meier method. P

Citation: Study provides clinician guidance on follow-up for ovarian cysts (2024, January 11)
retrieved 2 May 2024 from

<https://medicalxpress.com/news/2024-01-clinician-guidance-ovarian-cysts.html>

This document is subject to copyright. Apart from any fair dealing for the purpose of private study or research, no part may be reproduced without the written permission. The content is provided for information purposes only.