Medical Xpress

Morphology of vestibular aqueduct linked to Meniere disease

March 8 2024, by Elana Gotkine

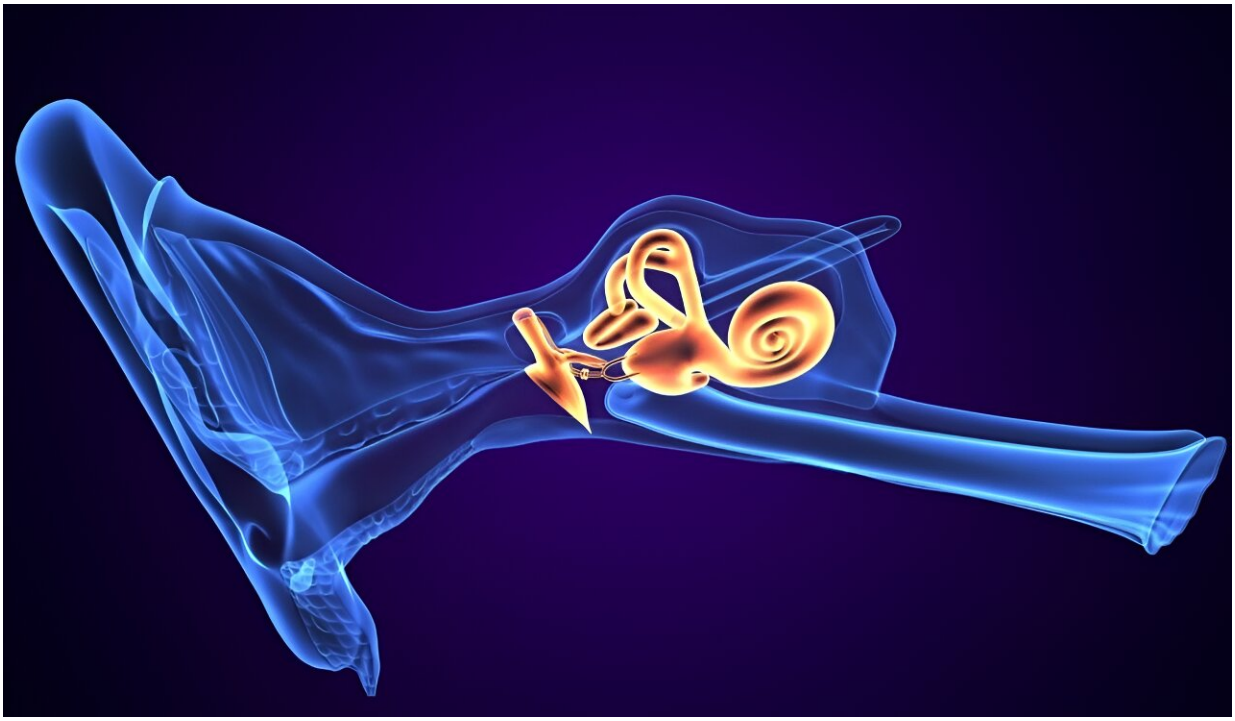

Morphological characteristics of the vestibular aqueduct (VA) are associated with the occurrence of Meniere disease (MD), according to a study published online Feb. 17 in *The Laryngoscope*.

Yan Huang, M.D., from Beijing Friendship Hospital, and colleagues

collected retrospective data from 34 patients (40 ears) diagnosed with MD who underwent temporal bone ultrahigh-resolution computed tomography (U-HRCT) with isotropic 0.05-mm resolution, magnetic resonance with gadolinium enhancement, and pure-tone audiometry; data were also included for 34 age- and sex-matched controls (68 ears) who underwent U-HRCT. VA patency was classified qualitatively as locally not shown, locally faintly shown, or clearly shown throughout (grades 1, 2, and 3, respectively). Differences in VA morphology were analyzed between the MD and control groups.

VA was classified as grades 1, 2, and 3 in 11, 17, and 12 ears and five, 26, and 37 ears in the MD and control groups, respectively, with a significant difference noted in patency between the groups. The researchers found that compared with the control group, the MD group had a significantly smaller width of the outer orifice and length of VA. Correlations were seen for both VA patency and length with the degree of endolymphatic hydrops in the cochlea and the vestibule. There was no difference noted between VA morphology and degree of hearing loss.

"Our results showed that the morphological characteristics of the VA, including a narrowed lumen and shortened length, may be related to MD, as well as the degree of endolymphatic hydrops," the authors write. "These findings may be beneficial for investigating the pathogenesis of MD from an anatomical perspective."

More information: Yan Huang et al, Association Between Vestibular Aqueduct Morphology and Meniere's Disease, *The Laryngoscope* (2024). DOI: 10.1002/lary.31339