Medical Xpress

Jackler on removing a tumor, saving a smile

February 22 2010

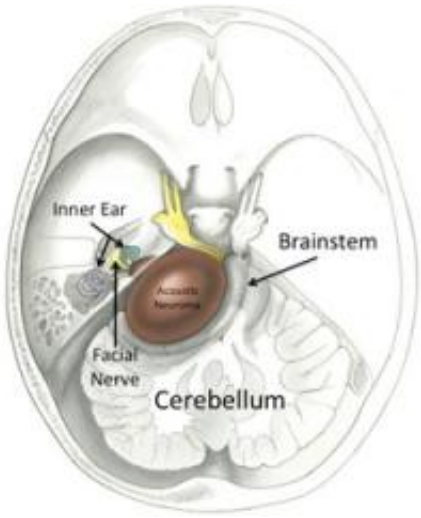

While acoustic neuromas are benign tumors, they must be removed before their growth puts fatal pressure on the brain.

(PhysOrg.com) -- Every doctor carries at least one patient in his or her head -- a memory of a difficult case, perhaps, or of a tragic outcome. And sometimes there's a patient who simply touches the heart. This is one in an occasional series about the patients they carry.

Robert Jackler, a skull base surgeon, has seen his share of tumors that push on the brain, but this one was a doozy—the "giant economy size" is the way he refers to it. The good news was the tumor was both benign and slow-growing. The bad news was it had been slowly growing inside the woman's skull for a very long time.

His prospective patient, Michele Young, was a Cincinnati attorney and mother of five, who sent him a copy of an MRI of her brain. It was obvious: Surgery would be required to save her life.

But Young wanted more than that. She wanted to preserve her ability to smile—and cry and blink and laugh—as well. She knew her chance of facial paralysis following this type of surgery was high.

“She was very much the ultimate consumer,” said Jackler, MD, professor and chair of otolaryngology, who first met Young when she flew out to Stanford for an interview. He appreciated just how selective she was about who was going to open her skull. She was shopping around.

The interview lasted more than an hour.

Jackler was impressed. The image of a “colorful, loquacious attorney” who was determined to preserve her quality of life has stayed with him.

Young left the interview convinced. She wanted her surgery to be done by the Stanford team.

When Young first discovered she had a large, and potentially deadly, tumor, she didn’t spend much time feeling sorry for herself. Instead, she turned her energy toward attacking it.

For years, Young had undiagnosed symptoms caused by the tumor that included loss of hearing, clumsiness, loss of memory and a tendency to veer to the right. What she didn’t know was that this tumor was pressing against her brain and gradually destroying the nerves that control her sense of balance and ability to hear. The bulky tumor mass could also cause a life-threatening buildup of pressure against the brain stem.

By the time she was diagnosed in March 2009, the tumor had grown to

the size of a large plum (4.9 cm).

Young made 10 copies of her MRI that she sent to 10 of the top medical centers across the country. Soon the experts started calling her back.

While much is known about the molecular genetics of these benign tumors, the underlying cause is unknown. Doctors do know how to treat them, but the therapy sometimes affects quality of life. If small and stable, the tumors can be left alone for years and just observed. If small but growing, treatment with stereotactic radiation (using the Cyberknife, for example) usually can control the tumor. Larger tumors need to be microsurgically removed, typically by a team of a neurotologist and neurosurgeon. Young's tumor was too big to be treated by radiation alone.

"We've long known we can save these patient's lives," Jackler said. "Acoustic neuromas cause damage by pressing on nerves, but they don't invade brain tissue like cancer does."

While success rates are high for removal, serious side effects are common. As the tumor grows, the facial nerve becomes stretched like a ribbon over the tumor surface. "The facial nerve often gets stuck on the tumor," Jackler said. "When the tumors are very large, the nerve becomes so integral to the tumor that a large percent of cases result in facial paralysis."

Over the past seven years, Jackler has helped pioneer an alternative treatment method he calls "combined therapy" that involves only partial removal of the tumor. "Think of the tumor like a tangerine. We remove all of the center and leave only the part of surface peel to which the facial nerve is attached," Jackler said. This is curative in most cases, but in one out of five patients a small recurrence arises over the first few years. Radiation is highly successful in controlling any small growths left

behind after the surgery.

This was the option Young had been looking for. “Facial paralysis is a big fear for me,” said Young, a political fundraiser, soccer coach and philanthropist in addition to mother and attorney. Her life hinges on her ability to communicate. “This option preserved the possibility of going back to my life. It preserved the ability to express myself and not be misunderstood when I tried to communicate.”

On April 29, 2009, Jackler and Griffith Harsh, MD, professor of neurosurgery, operated together to remove 95 percent of Young’s tumor. The delicate microsurgery stretched 14 hours. In the 10 months since the surgery, Young’s tumor has not grown back. Her MRIs look clear, Jackler said. And there is no facial paralysis.

“My clarity of thought and memory are back,” Young said. “My surgeons restored my brain to what it used to be. Now I’m back to my 24/7 life.”

Jackler added, “Our strategy was to control the tumor while maintaining a good quality of life. Facial expression was very important to Michele. She knew what she wanted. She was pretty hard to forget.”

Provided by Stanford University Medical Center

Citation: Jackler on removing a tumor, saving a smile (2010, February 22) retrieved 20 April 2024 from https://medicalxpress.com/news/2010-02-jackler-tumor.html

This document is subject to copyright. Apart from any fair dealing for the purpose of private study or research, no part may be reproduced without the written permission. The content is provided for information purposes only.