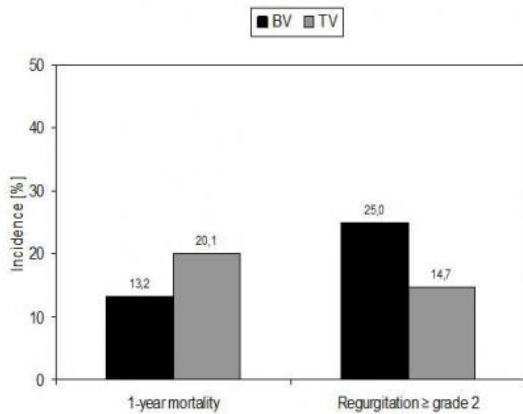


# TAVI feasible in bicuspid aortic valve

2 September 2013



Incidence of 1-year mortality and aortic regurgitation in patients with bicuspid (BV) and tricuspid (TV) aortic valve

Transcatheter aortic valve implantation (TAVI) is feasible in patients with bicuspid aortic valve, according to research presented at ESC Congress 2013 today by Dr. Timm Bauer from Germany. The findings open up a new treatment possibility in patients with BV, which has been considered a contraindication for TAVI.

Bicuspid aortic valve (BV) is the most common congenital valvular abnormality, occurring in 1-2% of the general population. Two of the aortic valvular leaflets fuse during development resulting in a valve that is bicuspid instead of the normal tricuspid configuration. BV is associated with increased [mechanical stress](#) which predisposes to [calcification](#) and development of aortic stenosis which narrows the opening of the aortic valve.

Dr Bauer said: "TAVI is used to treat elderly high [risk patients](#) with severe aortic stenosis. Despite previous assumptions the frequency of BV is quite high even among [elderly patients](#) with symptomatic aortic stenosis."

But he added: "BV has been considered a relative

contraindication to TAVI. One of the main reasons is the presumed risk for relevant aortic regurgitation, where blood leaks back through the aortic valve during ventricular diastole. However, case reports and small case series have suggested that TAVI can be successfully performed with acceptable [clinical outcomes](#) in high risk patients with BV."

The study prospectively enrolled 1,424 patients with [severe aortic stenosis](#) undergoing TAVI into the German TAVI-Registry between January 2009 and June 2010. For the present analysis patients with valve-in-valve procedures were excluded and those with BV (n=38, 2.7%) were compared to those with tricuspid aortic valve (TV) (n=1,357, 97.3%). Patient characteristics did not markedly differ and procedural success was very high in both groups.

The researchers found a higher rate of relevant aortic regurgitation (? grade 2) after TAVI among patients with BV (BV=25%, TV=14.7%; p=0.05) (see figure), whereas [pacemakers](#) were more often implanted in patients with TV (BV=16.7%, TV=35.4%; p=0.02). Dr Bauer said: "The higher rate of aortic regurgitation in BV patients was expected and is still acceptable because it did not lead to higher mortality. However, substantial improvements in the field of device technology and imaging have to be made to perform TAVI in a safer and more effective way in BV-patients."

He added: "The difference between groups in the need for a pacemaker can be partly explained by the higher implantation rate of Sapien Edwards<sup>TM</sup> prosthesis. Maybe anatomic differences in the aortic root or left ventricular outflow tract of BV play a role, too."

The 30-day mortality was similar in both cohorts (BV=10.5%, TV=10.8%). In a Cox proportional regression analysis after adjustment for several risk factors BV was not associated with higher 1-year mortality (hazard ratio [HR]=0.64, 95% confidence interval [CI]=0.29-1.41). Dr Bauer said: "Both 30-day and 1-year mortality were not elevated in

BV patients compared to patients with TV. We can therefore conclude that TAVI gave a satisfactory clinical outcome in BV patients despite their higher rate of relevant aortic regurgitation."

He concluded: "As the nature of our study is exploratory and the number of BV patients is quite low, the findings should be interpreted cautiously. However, our study opens up a new treatment possibility for selected [high risk](#) patients with BV, who until now have received medical treatment only or conventional valve surgery. TAVI has the potential to be a safe alternative in these [patients](#), but more studies are needed to support these findings."

Provided by European Society of Cardiology

APA citation: TAVI feasible in bicuspid aortic valve (2013, September 2) retrieved 18 October 2019 from <https://medicalxpress.com/news/2013-09-tavi-feasible-bicuspid-aortic-valve.html>

*This document is subject to copyright. Apart from any fair dealing for the purpose of private study or research, no part may be reproduced without the written permission. The content is provided for information purposes only.*