

# Neurophysiological assessment aids in identifying back injury

24 October 2014

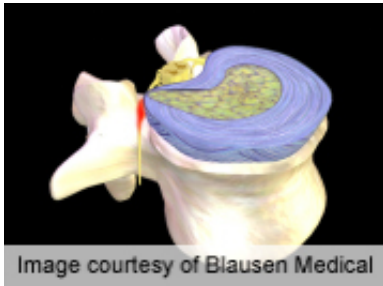


Image courtesy of Blausen Medical

(HealthDay)—For patients with lumbosacral disc herniation, neurophysiological tests together with neuroimaging and clinical examination allow for accurate preoperative assessment of injury, according to a study published in the Oct. 1 issue of *Spine*.

Magdalena Wojtysiak, M.D., Ph.D., from the Poznań University of Medical Sciences in Poland, and colleagues conducted a comparative analysis of preoperative and postoperative electromyography, electroneurography, F-waves, H-reflex, and motor evoked potentials (MEP) for 23 patients with confirmed disc-root conflict at lumbosacral spine. The patients also underwent clinical assessment, including examination of sensory perception for L5 to S1 dermatomes, muscle strength, deep tendon reflexes, pain intensity, and straight leg-raising test.

The researchers found that for evaluation of L5 to S1 roots injury, the sensitivity of electromyography at rest was 22 to 63 percent and of MEP examination was 31 to 56 percent; the corresponding specificities were 71 to 83 percent and 57 to 86 percent. For evaluation of S1 root injury, H-reflex sensitivity and specificity were 56 and 67 percent, respectively. For L5 and S1 root levels, there were significant improvements of root latency parameter in postoperative versus

preoperative MEP studies.

"The analysis of the results from neurophysiological tests together with [neuroimaging](#) and [clinical examination](#) allow for a precise preoperative indication of the lumbosacral roots [injury](#) and accurate postoperative evaluation of patients experiencing sciatica," the authors write.

**More information:** [Full Text \(subscription or payment may be required\)](#)

Copyright © 2014 [HealthDay](#). All rights reserved.

APA citation: Neurophysiological assessment aids in identifying back injury (2014, October 24) retrieved 24 October 2021 from <https://medicalxpress.com/news/2014-10-neurophysiological-aids-injury.html>

*This document is subject to copyright. Apart from any fair dealing for the purpose of private study or research, no part may be reproduced without the written permission. The content is provided for information purposes only.*