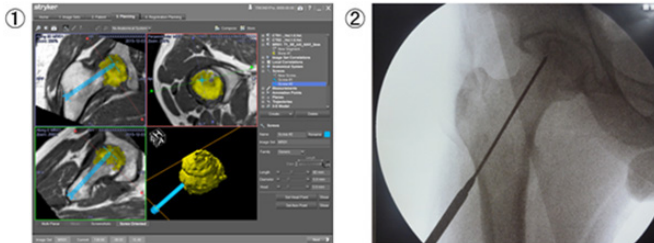


# Regenerative therapy shows promise for the treatment of femoral head osteonecrosis

1 April 2016



(Left) Pre-operative planning: In each of the four squares, the yellow area indicates the necrotic region of the femoral head and the blue line represents the route of bFGF injection. (Right) An X-ray image of the area being operated on: Using X-ray, bFGF-impregnated gelatin gel is injected into the affected area through a 5-mm-wide hole from a 1-cm-long incision made in the lateral surface of the femur.

As part of an ongoing investigator-initiated clinical trial, a medical team led by Professor Shuichi Matsuda of Kyoto University Hospital has successfully treated a patient with a refractory disease called idiopathic osteonecrosis of the femoral head (idiopathic ONFH). The procedure consisted of a single local administration of gelatin gel impregnated with basic fibroblast growth factor (bFGF), a protein that has been found to promote bone regeneration.

The patient, a male in his 30's, had the condition in both of his femoral heads, and participated in the trial with the hope of preventing the collapse of the necrotic bone—a common complication of the disease—through a minimally invasive bone-regeneration procedure.

The surgery was performed mid-February by a team headed by Assistant Professor Takashi Kuroda of KU Hospital. Under epidural anesthesia, the patient was injected with bFGF-impregnated gelatin gel through 1-cm-long incisions made in the

lateral surfaces of his femurs. The procedure was completed in about 15 minutes on each femoral head. Walking was allowed the following day, and the patient left the hospital on foot three days later.

The trial had been registered late January by a team from four domestic medical institutions, including KU Hospital's Institute for Advancement of Clinical and Translational Science (IACT), following approval from the Hospital's institutional review board.

The team is set to treat another 63 pre-collapse idiopathic ONFH patients over the coming months, and to follow them up for two years postoperatively to evaluate the efficacy and safety of the bFGF-based procedure, with the goal of making the technique ready for clinical application at an early date and eventually helping establish it as a standard treatment.

Idiopathic ONFH is a condition of unknown cause in which parts of the femoral head become necrotic due to decreased blood supply, resulting in severe impairment of hip mobility. In Japan, where it is recognized by the government as an intractable condition, about 3,000 new cases are reported each year, half of which are associated with steroid use. High-dose steroid therapy, a common treatment for systemic lupus erythematosus (SLE) and other connective-tissue diseases, has been identified as a major risk factor. Many of the patients are in their 20's and 30's.

In 70-80 percent of the cases, the condition progresses to cause the collapse of the affected bone. A collapsed femoral head is typically treated with a hip replacement, even in the case of young patients. This option, however, involves risks of postoperative infection, dislocation, and physical limitations, and hip implants deteriorate over time, all of which make pre-collapse regenerative therapy an ideal solution.

The regenerative effects of bFGF-impregnated gelatin gels have been proven through studies in which the use of the drug led to faster fracture healing. With ONFH, experiments conducted by Dr Kuroda and others demonstrated the gel's efficacy in preventing femoral head collapse in animal models, heightening expectations for clinical applications. Later, in 2013, the procedure was tested on 10 patients at KU Hospital, yielding results that indicated high efficacy and safety.

With successful outcomes, the present clinical trial could pave the way for the development and widespread adoption of a potent regenerative treatment for idiopathic ONFH.

Provided by Kyoto University

APA citation: Regenerative therapy shows promise for the treatment of femoral head osteonecrosis (2016, April 1) retrieved 5 December 2021 from <https://medicalxpress.com/news/2016-04-regenerative-therapy-treatment-femoral-osteonecrosis.html>

*This document is subject to copyright. Apart from any fair dealing for the purpose of private study or research, no part may be reproduced without the written permission. The content is provided for information purposes only.*