Medical Xpress

Findings to help radiologists ID zika virus infection at imaging

September 22 2016

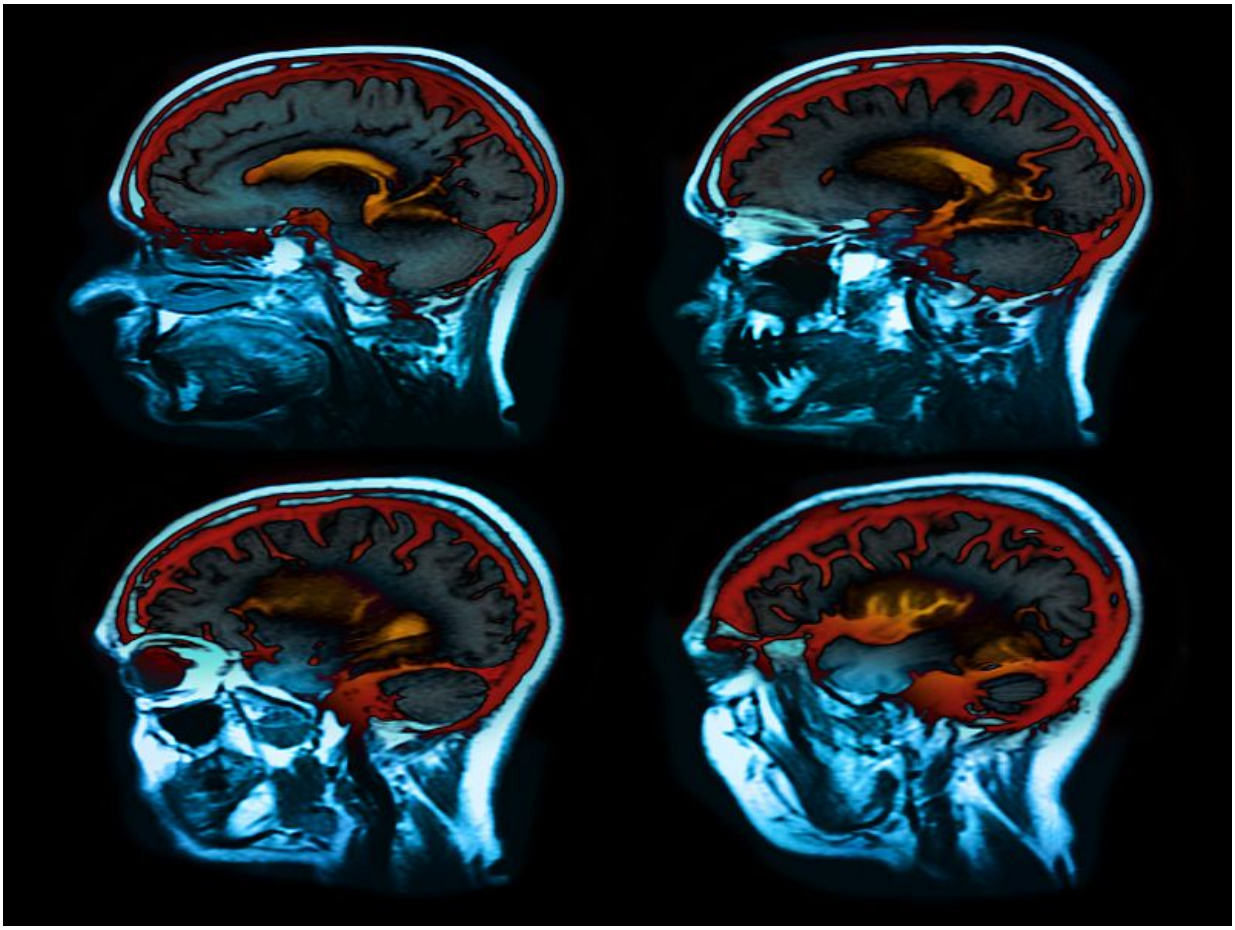

(HealthDay)—Congenital brain abnormalities are similar for confirmed

and presumed Zika infections, according to a study published in the October issue of *Radiology*.

Patricia Soares de Oliveira-Szejnfeld, M.D., from the Federal University of São Paulo in Brazil, and colleagues reviewed imaging for fetal magnetic resonance (MR) examinations, postnatal brain computed tomographic examinations, and postnatal brain MR examinations for 17 cases with confirmed Zika infection and 28 with presumed Zika infection.

The researchers observed similar brain abnormalities in confirmed and presumed congenital Zika infections, with ventriculomegaly seen in 94 and 96 percent, respectively; abnormalities of the corpus callosum in 94 and 78 percent, respectively; and cortical migrational abnormalities in 94 and 100 percent, respectively. In the presence of severe ventriculomegaly, head circumference could be normal (seen in three fetuses), although most fetuses underwent at least one examination that showed head circumference below the fifth percentile. Intracranial calcifications were most often observed at the junction of the gray matter and white matter (88 and 100 percent of confirmed and presumed infections, respectively). The skull often had a collapsed appearance, with overlapping sutures and redundant skin folds.

"The spectrum of findings associated with congenital Zika virus infection in the Instituto de Pesquisa in Campina Grande State Paraiba in northeastern Brazil is illustrated to aid the radiologist in identifying Zika virus infection at imaging," the authors write.

One author disclosed financial ties to the publishing industry.

More information: Abstract
Full Text

Medical Xpress

Copyright © 2016 HealthDay. All rights reserved.

Citation: Findings to help radiologists ID zika virus infection at imaging (2016, September 22) retrieved 18 September 2024 from https://medicalxpress.com/news/2016-09-radiologists-id-zika-virus-infection.html

This document is subject to copyright. Apart from any fair dealing for the purpose of private study or research, no part may be reproduced without the written permission. The content is provided for information purposes only.