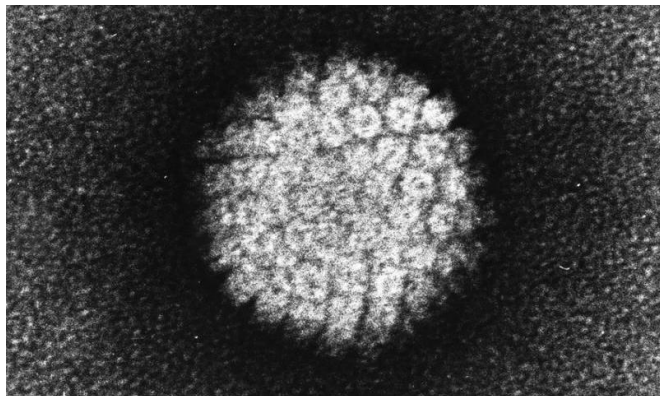


# Screening for cervical abnormalities in women offered HPV vaccination

19 September 2017



Electron micrograph of a negatively stained human papilloma virus (HPV) which occurs in human warts. Credit: public domain

Human papillomavirus (HPV) testing detects a higher number of precancerous cervical lesions than cytology-based Pap smears in a female population including a proportion offered HPV vaccination, according to a new study published in *PLOS Medicine* by Karen Canfell of Cancer Council New South Wales, Australia, researchers at the Victorian Cytology Service, Melbourne, Australia, and colleagues.

Many countries are currently considering switching from classic Pap tests to primary HPV tests for cervical cancer [screening](#), based on the strong evidence linking cervical abnormalities and infection with certain HPV types, and data suggesting that HPV tests detect more high-grade precancerous lesions. However, no study has yet compared the different methods in a population in which younger women had been offered prior HPV vaccination.

In the new Compass pilot study, researchers randomized cervical samples from 4,995 women aged 25-64 in Australia, in a 1:2:2 ratio, to be

analyzed by either [cytology](#) (with HPV testing of low-grade abnormalities), HPV testing with partial genotyping of the virus for the highest risk types HPV16 and 18, and cytology (for participants with other high-risk HPV genotypes), or HPV testing with partial genotyping and dual-stained cytology. In the first screening round of the trial, the authors assessed the rates of women being referred for further testing and of detection of CIN2+ (high-grade [cervical intraepithelial neoplasia](#)) precancerous lesions.

For the cytology group, the overall referral and detected CIN2+ rates were 27/995 (2.7% [95%CI 1.8-3.9]) and 1/995 (0.1% [95%CI 0.0-0.6]), respectively; for the HPV testing and cytology group these were 75/1992 (3.8% [95%CI 3.0-4.7]) and 20/1992 (1.0% [95%CI 0.6-1.5]); and for the HPV and dual-stained cytology group these were 79/2008 (3.9% [95%CI 3.1-4.9]) and 24/2008 (1.2% [95%CI 0.8-1.6]). The researchers found that, in the first round of screening, detection of CIN2+ was significantly increased with HPV testing as compared with cytology, while referral was non-significantly increased. Adverse events were rare, and the one case of early-stage cervical cancer (in the HPV testing plus cytology group) was detected as appropriate by screening.

"These findings provide initial confirmation of an improved performance of primary HPV screening compared to cytology screening in settings with HPV-vaccinated populations," said Dr. Canfell. These findings support the planned imminent introduction of cervical screening by HPV testing in Australia which will occur at the end of 2017.

**More information:** Canfell K, Caruana M, Gebiski V, Darlington-Brown J, Heley S, Brotherton J, et al. (2017) Cervical screening with primary HPV testing or cytology in a population of women in which those aged 33 years or younger had previously been offered HPV vaccination: Results of the Compass pilot randomised trial. *PLoS Med* 14(9): e1002388.

[doi.org/10.1371/journal.pmed.1002388](https://doi.org/10.1371/journal.pmed.1002388)

Provided by Public Library of Science

APA citation: Screening for cervical abnormalities in women offered HPV vaccination (2017, September 19) retrieved 25 October 2021 from <https://medicalxpress.com/news/2017-09-screening-cervical-abnormalities-women-hpv.html>

*This document is subject to copyright. Apart from any fair dealing for the purpose of private study or research, no part may be reproduced without the written permission. The content is provided for information purposes only.*