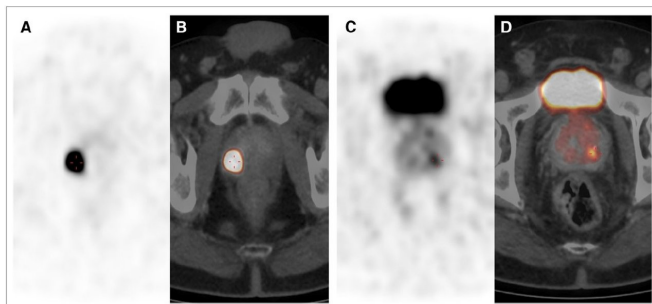


# PSMA PET/CT clearly differentiates prostate cancer from benign tissue

5 February 2018



(A and C) Axial PET images. (B and D) Fused PET/CT images. SUV<sub>max</sub> of lesion in B was 84.3 and that of lesion in D was 5.7. IRS was 3, and 80% of cells were stained. Credit: Senior author V Prasad, Charité Universitätsmedizin Berlin, Berlin, Germany.

Using nuclear medicine, German researchers have found a way to accurately differentiate cancerous tissue from healthy tissue in prostate cancer patients. The research is highlighted in the February issue of *The Journal of Nuclear Medicine*.

According to the American Cancer Society, one in nine men will be diagnosed with [prostate cancer](#) in his lifetime. Early diagnosis is key to successful treatment.

The new study demonstrates that the maximum standardized uptake value (SUV<sub>max</sub>) on Gallium-68 prostate specific membrane antigen (<sup>68</sup>Ga-PSMA) PET/CT scans correlates with PSMA-expression in primary prostate [cancer](#). By this means, researchers were able to generate an SUV<sub>max</sub> cutoff for the differentiation of cancerous and benign prostate tissue.

"To the best of our knowledge, this was the first study to generate a cutoff SUV<sub>max</sub>, validated by immunohistochemistry, for separating prostate

cancer from normal prostate tissue by <sup>68</sup>Ga-PSMA PET/CT images," explains Vikas Prasad, MD, PhD, of Charité Universitätsmedizin Berlin in Germany. "Our SUV<sub>max</sub> cutoff can be used to confirm or rule out prostate cancer with a very high degree of sensitivity and specificity."

He points out, "Recent years have brought tremendous advances in image-based biopsy of the prostate. However, in many patients, histopathology may not yield correct diagnosis (e.g., if the tumor is missed during true-cut biopsy). This is especially true for multifocal prostate cancer, less aggressive tumors, and cases of prostatitis or prior prostate irradiation, where MRI alone may not give the correct localization and malignancy grade."

For the study, the data of 31 men (mean age of 67.2 years) who had undergone prostatectomies and preoperative PET scans were analyzed, with the SUV<sub>max</sub> generated for suspicious areas and visually normal tissue. Both cancerous and benign prostate [tissue](#) samples (62 total) were stained with monoclonal anti-PSMA antibody. All the cancerous lesions could be confirmed histopathologically. The best cut-off value was determined to be 3.15 (sensitivity 97 percent, specificity 90 percent).

Prasad notes, "This validated cutoff of 3.15 for SUV<sub>max</sub> enables the diagnosis of prostate cancer with a high sensitivity and specificity in both unifocal and multifocal disease." Looking ahead, he posits, "With advancement of image-registration/segmentation software and PET/MRI scanners, it is quite logical to predict that in the future PET images and SUV<sub>max</sub> on a suspicious lesion in the [prostate](#) will be used for multimodal image-guided fusion biopsy."

**More information:** Nadine Woythal et al, Immunohistochemical Validation of PSMA Expression Measured by <sup>68</sup>Ga-PSMA PET/CT in Primary Prostate Cancer, *Journal of Nuclear*

Medicine (2017). DOI: [10.2967/jnumed.117.195172](https://doi.org/10.2967/jnumed.117.195172)

Provided by Society of Nuclear Medicine and  
Molecular Imaging

APA citation: PSMA PET/CT clearly differentiates prostate cancer from benign tissue (2018, February 5)  
retrieved 22 October 2020 from <https://medicalxpress.com/news/2018-02-psma-petct-differentiates-prostate-cancer.html>

*This document is subject to copyright. Apart from any fair dealing for the purpose of private study or research, no part may be reproduced without the written permission. The content is provided for information purposes only.*