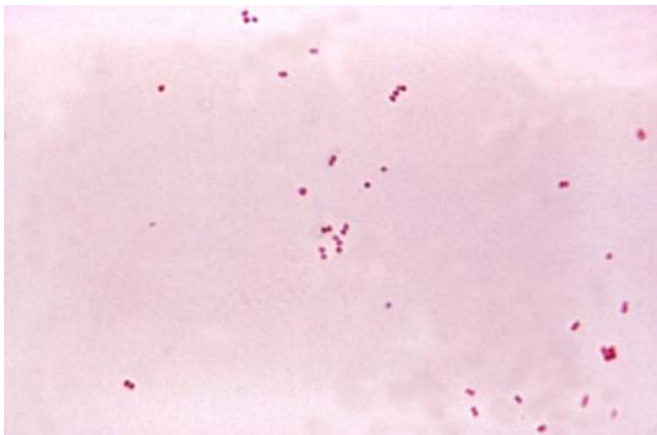


# PET scans to optimize tuberculosis meningitis treatments and personalize care, study finds

6 December 2018



Gram stain of meningococci from a culture showing Gram negative (pink) bacteria, often in pairs. Credit: public domain

Although relatively rare in the United States, and accounting for fewer than 5 percent of tuberculosis cases worldwide, TB of the brain—or tuberculosis meningitis (TBM)—is often deadly, always hard to treat, and a particular threat to young children. It may leave survivors with lifelong brain damage. Now, researchers at Johns Hopkins Medicine report they have used PET scans, a rabbit model and a specially tagged version of the TB drug rifampin to advance physicians' understanding of this disease by showing precisely how little rifampin ever reaches the sites of TB infection in the brain.

"Really precise information has never been easy to come by for how much rifampin gets to any given patient where it's needed," says corresponding author Sanjay Jain, M.D., professor of pediatrics, radiology and international health at the Johns Hopkins University School of Medicine. "We've been able to use technology to find that long-

needed information about this very troubling disease."

Jain, along with lead authors Elizabeth Tucker, M.D., assistant professor of anesthesiology and critical care medicine, and Alvaro Ordonez, M.D., research associate, pediatric infectious diseases at the Johns Hopkins University School of Medicine, as well as other Johns Hopkins and University of Maryland colleagues, published their findings Dec. 5 in *Science Translational Medicine*.

Tuberculosis, which mostly infects the lungs, sickens more than 10 million people around the world each year, causes more than 1 million deaths and costs the global economy billions of dollars, according to the World Health Organization. TBM, caused when *Mycobacterium tuberculosis* infects brain tissue and the fluid surrounding the brain and spinal cord, is considered the most lethal and disabling form of TB. Children under the age of 5, and those with chronic diseases—notably diabetes and HIV—are mostly likely to develop TBM. Like all TB diseases, TBM is treated with a combination of drugs, including isoniazid, rifampin and pyrazinamide, taken for a year. However, even with treatment, over half of patients die or have significant neurological injury lasting a lifetime, especially [young children](#).

In the new study, Johns Hopkins researchers engineered a version of rifampin with a charged particle—called a positron—attached to the [drug](#) ( $[^{11}\text{C}]$ rifampin) that allowed them to follow its movement throughout the body using PET (positron emission tomography) scans.

Because TBM symptoms are similar among rabbits and humans, the researchers created an experimentally infected colony of rabbits with TBM, injected them with the tagged drug and tracked

levels of the tagged [11C]rifampin throughout the rabbits' brains over six weeks. PET scans revealed that after two weeks of treatment, the penetration of [11C]rifampin into TBM brain lesions significantly decreased, from 32 percent to only 11 percent of the levels of the drug noted in the blood.

Significantly, they say, the decrease was not reflected in samples of cerebrospinal fluid (CSF) taken from the rabbits, despite that CSF is currently used as a standard proxy for determining drug and infection levels in people.

"Until now, when treating patients, we've relied on a needle biopsy," says Tucker. "We've assumed that what's happening at the tip of the needle at one time point in a sample is what's happening throughout the affected organ." The new results in the rabbit model, she says, suggest that it's not that simple, at least in the animals. The penetration of rifampin varied among TBM lesions even within a single animal, and changed over the course of the long treatment timeline.

The researchers also gave the tagged version of the drug to 10 adult human TB patients already receiving rifampin therapy. The patients were scanned at the Johns Hopkins PET Center in Baltimore, and these studies were performed under Food and Drug Administration guidelines for new PET tracers. One of the patients, a 24-year-old female, had TBM. Similar to the results in rabbits, a PET scan showed that penetration of the drug into the patient's brain lesions was limited to less than 5 percent.

The findings, the researchers say, help advance understanding of why current drug treatments for TBM may not be as effective. And they say the PET approach offers a potential way to optimize the treatment of TBM, to ensure that enough drug is reaching the infected lesions.

"If further research in animals and humans confirms that [rifampin](#) and other anti-TB drugs penetrate differently into their brains," says Ordonez, "we foresee that imaging can help us figure out the concentration of drug needed and tailor the dose for individual patients."

The team also expects that the rabbit model of

TBM can be used to answer key questions about the disease and its treatment, including what baseline levels of antibiotics are required to penetrate [brain](#) lesions more fully.

"We used to think we could just give a drug and patients should get better," says Jain. "Now, we have tools to measure the nuances that make a difference. PET could be used to study other antibiotics and also allow precision medicine approaches in resource-rich settings, such as the U.S. for other serious infections including MRSA (methicillin-resistant *Staphylococcus aureus*)."

**More information:** Elizabeth W. Tucker et al, Noninvasive 11C-rifampin positron emission tomography reveals drug biodistribution in tuberculous meningitis, *Science Translational Medicine* (2018). DOI: [10.1126/scitranslmed.aau0965](https://doi.org/10.1126/scitranslmed.aau0965)

Provided by Johns Hopkins University School of Medicine

APA citation: PET scans to optimize tuberculosis meningitis treatments and personalize care, study finds (2018, December 6) retrieved 17 December 2018 from <https://medicalxpress.com/news/2018-12-pet-scans-optimize-tuberculosis-meningitis.html>

*This document is subject to copyright. Apart from any fair dealing for the purpose of private study or research, no part may be reproduced without the written permission. The content is provided for information purposes only.*