Medical Xpress

New 'tracers' improve diagnosis of cancer and may be useful for treatment

March 11 2019

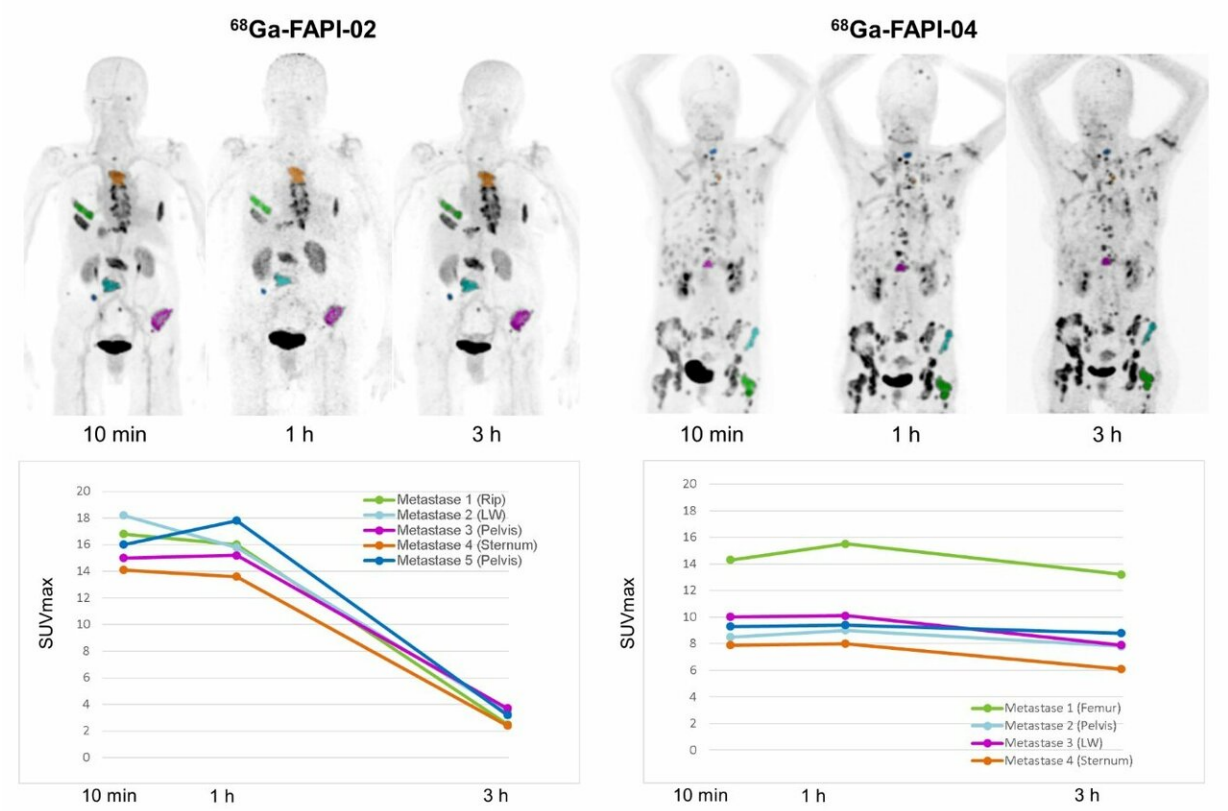

68Ga-FAPI-2 and 68Ga-FAPI-4 at 10 minutes, 1 hour, and 3 hours after injection. Rapid tumor targeting and fast blood clearance are followed by long plateau phase without relevant change in image contrast (top). In comparison to 68Ga-FAPI-2, 68Ga-FAPI-4 is characterized by prolonged tumor retention time (bottom). LW = lumbar body. Credit: Giesel FL, Kratochwil C, Lindner T, et al.

Researchers have identified two new nuclear medicine tracers that make it easier to diagnose and potentially treat cancer. A proof-of-concept investigation, published in the March issue of *The Journal of Nuclear Medicine*, reports that 68Ga-FAPI positron emission tomography/computed tomography (PET/CT) provides high-contrast images with quality equal to or better than that of the standard 18F-FDG imaging. Further, no diet changes or fasting are needed before beginning imaging with 68Ga-FAPI, and image acquisition times are substantially shorter than with 18F-FDG PET/CT.

"Having an additional diagnostic tool opens up a new door for cancer patients," said Uwe Haberkorn, MD, professor of nuclear medicine at the University Hospital of Heidelberg and the German Cancer Research Center in Heidelberg, Germany. "For those who are facing unmet diagnostic challenges—unclear tumor segmentation for radiation therapy , suspicion of false-negative findings, or selection of last-line experimental treatment—68Ga-FAPI may help to provide answers."

In processes involving remodeling of tissue (e.g., wound healing), cells called fibroblasts are activated by several factors, including TGF?? leading to the expression of the fibroblast activation protein (FAP). This protein is produced in abnormally large amounts in cancer-associated fibroblasts (CAFs), which promote tumor growth, migration and progression. 68Ga-FAPI is a new class of radiopharmaceutical that can precisely target CAF activity to aid physicians in diagnosis of cancer. As CAFs are present in more than 90 percent of epithelial carcinomas—including, for example, breast, lung, colon, pancreatic, and head and neck cancers—they are an attractive target for both diagnostic imaging and therapy.

The 50 patients in this analysis were referred by oncologists who were facing unmet diagnostic challenges that could not be solved sufficiently with standard diagnostic means. All patients tolerated the examination

well, and no patients reported any symptoms. The favorable characteristics of the new tracers include fast kinetics that seem appropriate for imaging patients even less than 1 h after injection; low background uptake in liver, oral mucosa, and brain; and independence from blood sugar.

Patients benefited from needing no diet changes or preparation for the PET/CT imaging. "A shorter waiting time and shorter scan time can increase patient comfort, which can be especially important for sick patients," Haberkorn stated. "The possibility of early imaging—for example, after only 10 minutes instead of an hour—could also play a part in simplifying clinical workflow."

Since CAFs are genetically more stable than cancer cells, they are less likely to develop resistance to therapy. Also, as the FAPI tracers contain the universal DOTA-chelator, a theranostic approach seems feasible.

"FAPI tracers are a promising avenue for cancer treatment," Haberkorn noted. "What's more, in the future FAPI imaging may also be used to assess and manage cardiac diseases or fibrotic diseases of the lung, liver and kidneys."

More information: Frederik L. Giesel et al, 68Ga-FAPI PET/CT: Biodistribution and Preliminary Dosimetry Estimate of 2 DOTA-Containing FAP-Targeting Agents in Patients with Various Cancers, *Journal of Nuclear Medicine* (2018). DOI: 10.2967/jnumed.118.215913

Provided by Society of Nuclear Medicine and Molecular Imaging

Citation: New 'tracers' improve diagnosis of cancer and may be useful for treatment (2019, March 11) retrieved 20 April 2024 from https://medicalxpress.com/news/2019-03-tracers-

diagnosis-cancer-treatment.html

This document is subject to copyright. Apart from any fair dealing for the purpose of private study or research, no part may be reproduced without the written permission. The content is provided for information purposes only.