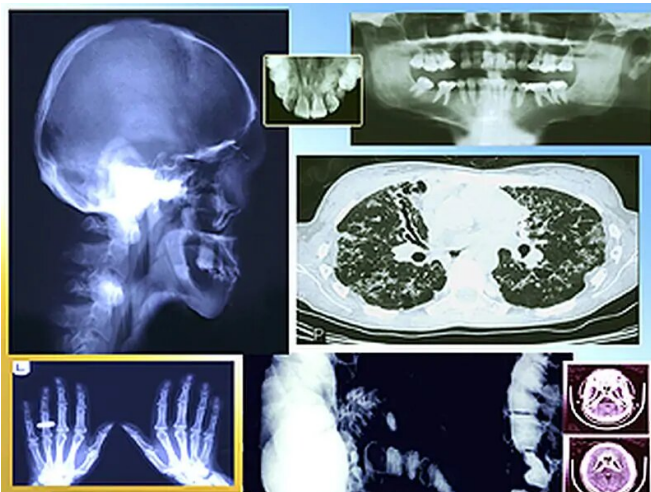


# New, revised topics released in ACR appropriateness criteria

9 April 2019



prostatic hyperplasia; suspected neoplasm in the case of palpable abdominal mass; penetrating trauma in the lower abdomen and pelvis; posttreatment follow-up and [active surveillance](#) of clinically localized [renal cell cancer](#); posttreatment bladder cancer surveillance; initial workup and surveillance for local recurrence and distant metastases in asymptomatic women with stage I breast cancer; and suspected osteomyelitis of the foot in diabetes.

"We encourage radiology professionals to review these updates and provide feedback and comments via our recently enhanced comment site," Frank J. Rybicki, M.D., Ph.D., chair of the ACR Committee on Appropriateness Criteria, said in a statement.

**More information:** [More Information](#)

(HealthDay)—The latest edition of the American College of Radiology (ACR) Appropriateness Criteria has been released and includes 188 diagnostic imaging and interventional radiology topics, with 908 clinical variants covering more than 1,670 clinical scenarios.

Copyright © 2019 [HealthDay](#). All rights reserved.

The update includes two new topics: clinically suspected vascular malformation of the extremities and gestational trophoblastic disease (GTD). For vascular malformation of the upper or lower extremities, [magnetic resonance angiography](#), magnetic resonance imaging, computed tomography angiography, and ultrasound (US) duplex Doppler of the extremity area of interest are usually appropriate. For suspected or initial diagnosis of GTD, US examinations are usually appropriate.

In addition, 10 topics have been revised, including [acute pancreatitis](#); acute respiratory illness in immunocompromised patients; headache; lower urinary tract symptoms suspicious of benign

APA citation: New, revised topics released in ACR appropriateness criteria (2019, April 9) retrieved 22 October 2020 from <https://medicalxpress.com/news/2019-04-topics-acr-appropriateness-criteria.html>

*This document is subject to copyright. Apart from any fair dealing for the purpose of private study or research, no part may be reproduced without the written permission. The content is provided for information purposes only.*