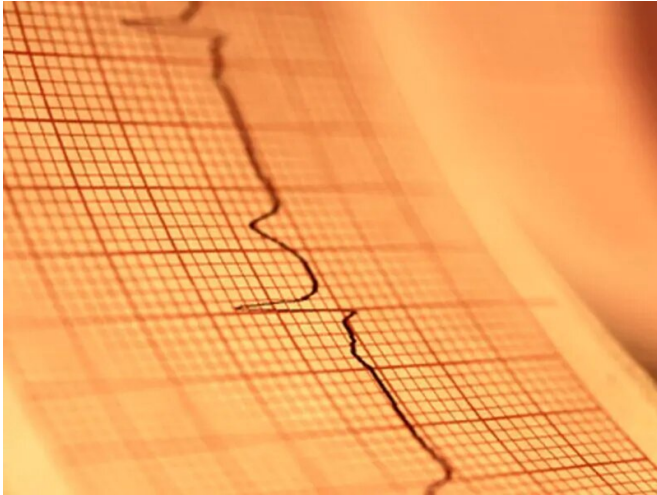


ST-segment elevation described in patients with COVID-19

22 April 2020



ventricular ejection fraction, one of whom had a regional wall-motion abnormality. Eight patients had a reduced left ventricular ejection fraction. Nine patients underwent [coronary angiography](#) and six of these had obstructive disease; five patients underwent percutaneous coronary intervention. Higher median peak troponin and D-dimer levels were seen among the eight patients who received a clinical diagnosis of myocardial infarction versus the 10 with noncoronary myocardial injury. Thirteen patients died in the hospital, including four and nine with myocardial infarction and noncoronary myocardial injury, respectively.

"In this series of [patients](#) with COVID-19 who had ST-segment elevation, there was variability in presentation, a high prevalence of nonobstructive disease, and a [poor prognosis](#)," the authors write.

More information: [Abstract/Full Text](#)

(HealthDay)—For patients with COVID-19 who have ST-segment elevation, indicating potential acute myocardial infarction, there is considerable variability in presentation, and prognosis is poor, according to a letter to the editor published online April 17 in the *New England Journal of Medicine*.

Sripal Bangalore, M.D., from New York University Grossman School of Medicine in New York City, and colleagues describe their experience involving patients with confirmed COVID-19 who had ST-segment elevation on electrocardiography from six New York hospitals.

The researchers identified 18 patients with ST-segment elevation indicating potential acute myocardial infarction ([median age](#), 63 years; 83 percent male), of whom 33 percent had chest pain around the time of ST-segment elevation. Ten patients had ST-segment elevation at the time of presentation and eight developed ST-segment elevation during hospitalization. Five of 14 patients with focal ST-segment elevation had a normal left

Copyright © 2020 [HealthDay](#). All rights reserved.

APA citation: ST-segment elevation described in patients with COVID-19 (2020, April 22) retrieved 27 January 2022 from <https://medicalxpress.com/news/2020-04-st-segment-elevation-patients-covid-.html>

This document is subject to copyright. Apart from any fair dealing for the purpose of private study or research, no part may be reproduced without the written permission. The content is provided for information purposes only.