Medical Xpress

CT identifies patients with high-risk nonalcoholic fatty liver disease (NAFLD)

January 22 2021

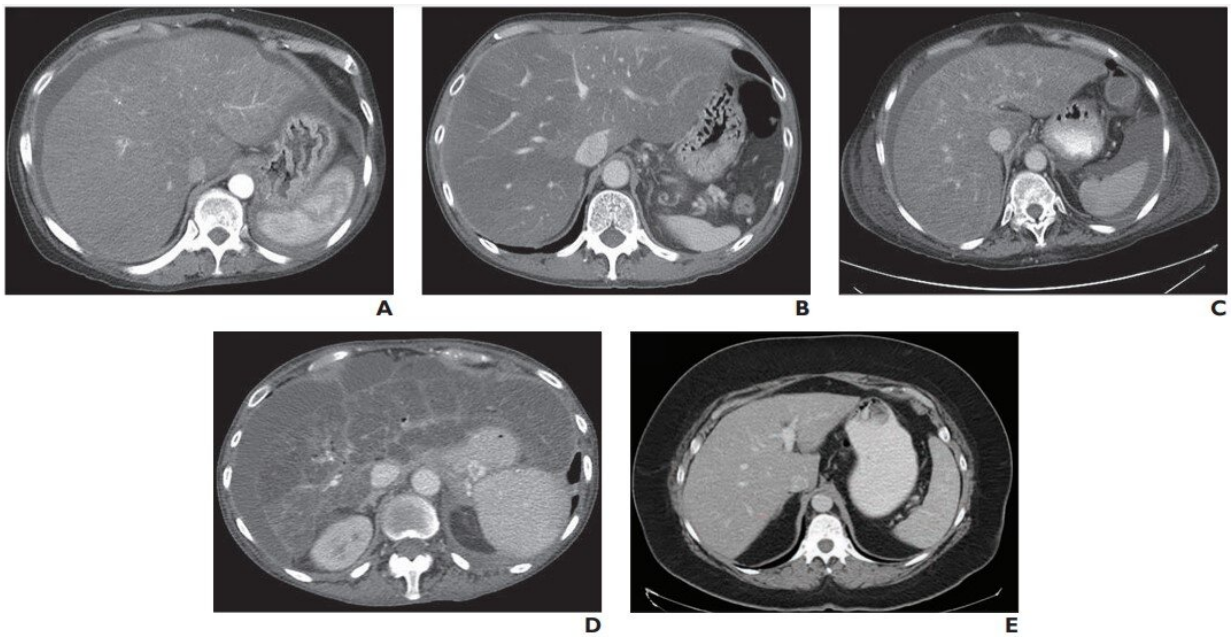

A and B, True-positive assessments in 58-year-old woman (A) and 52-year-old man (B) with high-risk NAFLD and associated NASH. CT images show hepatic enlargement, heterogeneously low-attenuation hepatic parenchyma, and surrounding ascites. Readers correctly identified NASH according to these imaging features. Readers also correctly identified fibrosis stage F3.C and D, False-positive assessments in 73-year-old woman (C) and 61-year-old woman (D) with high-risk NAFLD but without pathologic evidence of NASH. CT images show findings similar to A and B. Readers incorrectly identified NASH because of these imaging findings but correctly identified fibrosis stages F3 (C) and F4 (D).E, False-negative assessment in 56-year-old woman. CT image shows liver is not enlarged, heterogeneous, or low in attenuation, and ascites is not present. Both readers interpreted image as not showing findings indicative of

NASH. However, NASH was diagnosed from surgical pathology. Credit: American Roentgen Ray Society (ARRS), American Journal of Roentgenology (AJR)

According to ARRS' *American Journal of Roentgenology* (AJR), Fibrosis-4 (FIB-4) and multiple CT findings can identify patients with high-risk nonalcoholic fatty liver disease (NAFLD)—advanced fibrosis or cirrhosis, that is—though the presence of nonalcoholic steatohepatitis (NASH) remains elusive on CT.

"Subjective assessment of multiple morphologic and separately quantified parameters by trained readers and a simple quantitative three-parameter model combining two CT features, liver surface nodularity (LSN) and liver segmental volume ratio (LSVR), and a clinical score (FIB-4) showed good association with presence of advanced fibrosis," wrote first author Meghan G. Lubner from the department of radiology at the University of Wisconsin School of Medicine and Public Health.

Based on a presentation at the ARRS 2019 Annual Meeting, Honolulu, HI, patients with biopsy-proven NAFLD who underwent CT within 1 year of biopsy were included. An experienced gastrointestinal pathologist performed a histopathologic review to determine steatosis, inflammation, and fibrosis. The presence of any lobular inflammation and hepatocyte ballooning was categorized as nonalcoholic steatohepatitis (NASH), while patients with NAFLD and advanced fibrosis (stage F3 or higher) were categorized as having high-risk NAFLD. Two readers subjectively assessed the presence of NASH and fibrosis.

The final cohort consisted of 186 patients (mean age, 49 years; 112 women and 74 men), of whom 87 (47%) had NASH and 112 (60%) had

moderate to severe steatosis. A total of 51 patients were classified as fibrosis stage F0, 42 as F1, 23 as F2, 37 as F3, and 33 as F4. Additionally, 70 (38%) had advanced fibrosis (stage F3 or F4) and were considered to have high-risk NAFLD. FIB-4 score showed correlation with fibrosis, and of the individual CT parameters, LSVR and splenic volume had the best performance. Meanwhile, subjective reader assessment performed best among all parameters. FIB-4 and subjective scores were complementary, and for NASH assessment, FIB-4 performed best.

Noting the well-established utility of CT in identifying hepatic steatosis, the authors of this AJR article concluded that CT can also be "a highly accessible, frequently used method for assessment of patients with NAFLD and identification of those with high-risk NAFLD (advanced fibrosis or cirrhosis) who are potentially most in need of intervention."

More information: Meghan G. Lubner et al, Utility of Multiparametric CT for Identification of High-Risk NAFLD, *American Journal of Roentgenology* (2021). DOI: 10.2214/AJR.20.22842

Provided by American Roentgen Ray Society

Citation: CT identifies patients with high-risk nonalcoholic fatty liver disease (NAFLD) (2021, January 22) retrieved 25 April 2024 from https://medicalxpress.com/news/2021-01-ct-patients-high-risk-nonalcoholic-fatty.html

This document is subject to copyright. Apart from any fair dealing for the purpose of private study or research, no part may be reproduced without the written permission. The content is provided for information purposes only.