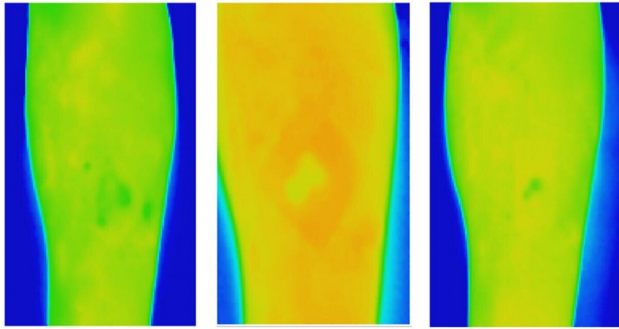


Thermal imaging offers early alert for chronic wound care

30 June 2021



Thermal images of a venous leg ulcer showing healthy healing progress over three weeks. Credit: RMIT University

Researchers found the method, which provides information on spatial heat distribution in a wound, could accurately predict whether VLUs would heal in 12 weeks by the second week after baseline assessment.

This is because wounds change significantly over the healing trajectory, with higher temperatures signaling potential inflammation or infection while lower temperatures can indicate a slower healing rate due to decreased oxygen in the region.


Bolton Clarke Research Institute Senior Research Fellow Dr. Rajna Ogrin said the current gold standard for predicting healing of VLUs—conventional digital planimetry—requires physical contact.

New research shows thermal imaging techniques can predict whether a wound needs extra management, offering an early alert system to improve chronic wound care.

It is estimated that 1-2% of the population will experience a chronic wound during their lifetime in developed countries—in the US, chronic wounds affect about 6.5 million patients with more than US\$25 billion each year spent by the healthcare system on treating related complications.

The Australian study shows textural analysis of thermal images of venous leg ulcers (VLUs) can detect whether a wound needs extra management as early as week two for clients receiving treatment at home.

The [clinical study](#) by RMIT University and Bolton Clarke, published in the *Nature* journal *Scientific Reports*, is the first to investigate textural analysis on VLUs using thermal images that do not require physical contact with the wound.



Thermal images of a venous leg ulcer that ultimately failed to heal. The images, taken over three weeks early in the healing process, can be used to predict that a VLU will not heal normally at week 12 and needs extra care. Credit: RMIT University

"A non-contact method like [thermal imaging](#) would be ideal to use when managing wounds in the home setting to minimize physical contact and therefore reduce infection risk," Ogrin said.

After showing that traditional thermal imaging methods do not give reliable results, the research team developed a new method for the analysis and used this in the clinical trial.

The new study, which involved 60 participants with VLUs, found thermal imaging offers an improvement on the current guidance for using digital imagery or planimetry wound tracings to detect the healing wounds by week four.

"The significance of this work is that there is now a method for detecting [wounds](#) that do not heal in the normal trajectory by week two using a non-contact, quick, objective and simple method," Ogrin said.

RMIT University Professor Dinesh Kumar said regular wound photography could not easily be used for accurate measurement of changes in wound size and other physiological parameters over time in the home care environment.

"This is because there are large variations between images due to changes in the lighting conditions, [image quality](#) and differences in camera angle across specific points in time," said Kumar, who leads the Biosignals for Affordable Healthcare group in RMIT's School of Engineering.

"Textural analysis of thermal images is resilient to these variations and is a time-efficient and cost-effective method to identify delayed [healing](#) of VLUs and improve patient outcomes."

More information: Mahta Monshipouri et al, Thermal imaging potential and limitations to predict healing of venous leg ulcers, *Scientific Reports* (2021). [DOI: 10.1038/s41598-021-92828-2](https://doi.org/10.1038/s41598-021-92828-2)

Provided by RMIT University

APA citation: Thermal imaging offers early alert for chronic wound care (2021, June 30) retrieved 21 October 2021 from <https://medicalxpress.com/news/2021-06-thermal-imaging-early-chronic-wound.html>

This document is subject to copyright. Apart from any fair dealing for the purpose of private study or research, no part may be reproduced without the written permission. The content is provided for information purposes only.