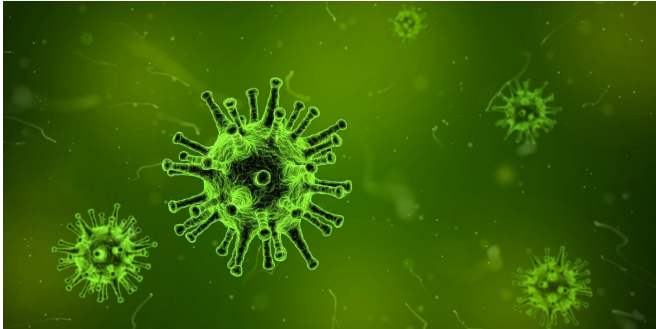


First Aussie case of rare inflammatory syndrome following COVID-19 infection

15 October 2021



Credit: Pixabay/CC0 Public Domain

Doctors from the Children's Hospital at Westmead in Sydney have identified the first known case of multisystem inflammatory syndrome in an adult in Australia, according to a Letter to the Editor published today by the *Medical Journal of Australia*.

Multisystem inflammatory syndrome (MIS-A) is a rare but severe systemic inflammatory syndrome occurring 4–6 weeks after COVID-19 infection. It is more commonly seen in children, where it is known as pediatric inflammatory multisystem [syndrome](#) temporally associated with SARS-CoV-2 (PIMS-TS).

Dr. Annaleise Howard-Jones and colleagues reported that a 42-year-old woman presented with 7 days of fevers, muscle aches and pains, light-headedness, abdominal pain, nausea, heart palpitations and non-pleuritic chest pain. She also had infection in both eyes, a widespread blanching rash, and swelling of both hands.

"This occurred 27 days following a confirmed case of acute COVID-19 pneumonitis," Howard-Jones and colleagues reported. "The acute illness was mild, requiring neither oxygen nor hospitalization, and the patient recovered fully 72 hours before

onset of this new symptom complex. She was unimmunised against SARS-CoV-2."

The patient responded to two doses of intravenous immunoglobulin (2g/kg each) following 48 hours' of metaraminol infusion then low dose noradrenaline. Aspirin (3mg/kg daily) was administered, as well as IV antibiotics for 72 hours.

"Adults and adolescents with MIS-C/A typically present with multisystem involvement often incorporating myocarditis, shock and gastrointestinal features whereas [younger children](#) present more commonly with a Kawasaki disease-like illness," Howard-Jones and colleagues reported.

"Given the absence of specific diagnostic markers, the overlapping phenotype with [toxic shock syndrome](#) and the poor sensitivity of cultures and serological markers for these alternative diagnoses, such differentials must be carefully considered in the early phase of illness.

"Nonetheless, clinicians should be aware of MIS-C/A in patients presenting with shock, mucocutaneous changes and/or gastrointestinal symptoms, even without preceding symptomatic COVID-19 infection.

"Prompt treatment with intravenous immunoglobulin and/or steroids is essential to minimize long-term morbidity from coronary artery dilatation. While rare, further cases of MIS-C/A are anticipated following increasing COVID-19 case notifications in NSW and Victoria."

More information: Annaleise R Howard-Jones, Sam R Orde and Zoe Jennings, Australian case of multisystem inflammatory syndrome in adults (MIS-A) occurs two months into 2021 SARS-CoV-2 Delta outbreak in New South Wales, *Medical Journal of Australia* (2021). [DOI: 10.5694/mja2.51325](https://doi.org/10.5694/mja2.51325)

Provided by Medical Journal of Australia

APA citation: First Aussie case of rare inflammatory syndrome following COVID-19 infection (2021, October 15) retrieved 21 January 2022 from <https://medicalxpress.com/news/2021-10-aussie-case-rare-inflammatory-syndrome.html>

This document is subject to copyright. Apart from any fair dealing for the purpose of private study or research, no part may be reproduced without the written permission. The content is provided for information purposes only.